

Original
articleTissue specific HPV expression and
downregulation of local immune responses in
condylomas from HIV seropositive individuals

Istvan Arany, Tanya Evans, Stephen K Tyring

Objective: To study the effect of tissue specific human papillomavirus (HPV) expression and its effect on local immunity in condylomas from HIV positive individuals.

Methods: Biopsy specimens of eight penile and eight perianal condylomas from HIV seropositive individuals were analysed. Expression of viral genes (HIV-*tat* and HPV E7 and L1) was determined by RT-PCR. The status of local immunity also was determined by RT-PCR by measuring CD4, CD8, CD16, CD1a, HLA-DR, and HLA-B7 mRNA levels in the tissues. Differentiation was determined by measuring involucrin, keratinocyte transglutaminase, as well as cytokeratins 10, 16, and 17. Proliferation markers such as PCNA and *c-myc* were also determined.

Results: The transcription pattern of HPV in perianal condylomas, which preferentially expressed the early (E7) gene, was different from that of penile condylomas, which primarily expressed the late (L1) gene. This transcription pattern is in good correlation with the keratinisation and differentiation patterns of the two epithelia: perianal biopsies preferentially expressed K16 and K17 while penile warts mainly expressed K10, markers of parakeratotic and orthokeratotic epithelia, respectively. Perianal biopsies also showed a higher degree of proliferation (PCNA and *c-myc*). Interestingly, transcription of HIV-*tat* was also higher in perianal than in penile biopsies. A high degree of local immunodeficiency was observed in perianal biopsies—that is, levels of CD4, CD16, and CD1a mRNAs were significantly lower. A negative correlation between CD1a (Langerhans cells) levels and HPV E7 levels was established. HPV E7 levels positively correlated with HIV-*tat* levels. Perianal tissues demonstrated more CD1a depression and *tat* associated HPV upregulation.

Conclusion: HIV influences the expression of HPV genes resulting in local immunosuppression that might lead to an inappropriate immune surveillance of viral infection. Also, tissue type is an important factor in controlling viral transcription in a differentiation dependent manner. These findings may explain the higher rate of dysplasia and neoplasia in the perianal area.

(Sex Transm Inf 1998;74:349–353)

Keywords: human papillomavirus; HIV; condylomas; immunity

Introduction

Human papillomaviruses (HPVs) infect squamous epithelia causing benign or malignant lesions on mucosal and cutaneous surfaces.¹ Since benign HPV associated lesions do not disseminate, the local immune response is a key point in regulation of active infection.² However, HPVs can impair local immunity, as observed by decreases in the number of Langerhans cells,³ by downregulation of HLA expression,^{4,5} and by downregulation of immune cytokines.^{6–8} Our former studies demonstrated that HPV affects local immunity in a HPV early gene dependent fashion.⁹ Also, expression of HPV early genes depends on tissue type—that is, it correlates well with the status of differentiation and keratinisation.¹⁰

Numerous studies indicate that HIV infection may promote the clinical manifestations of subclinical or latent HPV infection.¹¹ Thus, a higher incidence of condyloma acuminatum^{12,13} and/or cervical disorders^{14–17} has been observed in the HIV affected population. HIV infection may influence the pathogenesis of HPV associated diseases either directly through molecular interactions between viral genes and/or indirectly through effects on the immune functions.¹¹ The relative

importance of altered systemic or local immune responses to HPV infection in HIV seropositive individuals, however, is neither well documented nor understood.

Accordingly, our aim was to study the tissue differentiation dependent HPV expression and its effects on local immunity in condylomas from HIV positive individuals.

Materials and methods

SPECIMENS

Eight penile and eight perianal condyloma biopsies were collected from HIV positive individuals. Each biopsy was bisected; one part was placed in formalin and one part frozen at -70°C . The formalin fixed section was subsequently determined by a board certified dermatopathologist to be condyloma acuminatum. The snap frozen part was stored in liquid nitrogen for further molecular analysis. HIV seropositivity and peripheral CD4 count were determined by routine laboratory diagnostic methods. Only one lesion was obtained per individual, however, we analysed and compared eight patients for penile and eight patients for perianal biopsies.

Department of
Microbiology and
Immunology,
University of Texas
Medical Branch,
Galveston, USA

I Arany
S K Tyring
T Evans

Department of
Dermatology,
University of Texas
Medical Branch,
Galveston, USA

S K Tyring
T Evans

Correspondence to:
Dr S K Tyring, Department
of Microbiology and
Immunology, The University
of Texas Medical Branch,
Galveston, TX 77555, USA.

Accepted for publication
8 July 1998

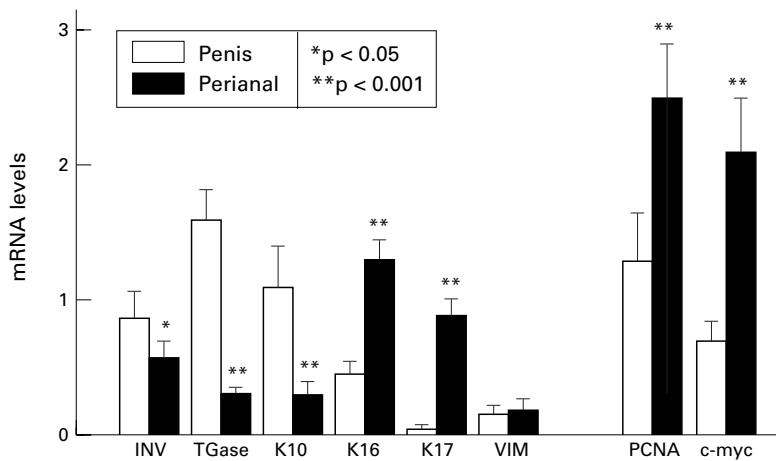


Figure 1 Status of differentiation, keratinisation, and proliferation in penile and perianal condyloma biopsies from HIV positive individuals. RNA was isolated from condylomas of the penis and perianal region. A semiquantitative RT-PCR method was employed to detect and compare mRNA levels for genes of differentiation and keratinisation (INV = involucrin; Tgase = keratinocyte transglutaminase; K10 = keratin 10; K16 = keratin 16; K17 = keratin 17), proliferation (PCNA = proliferating cell nuclear antigen; c-myc = c-myc oncogene), and vimentin (VIM). mRNA levels were expressed as ratios of target gene normalised to G3PDH. Data are given as mean (SD) (n=8).

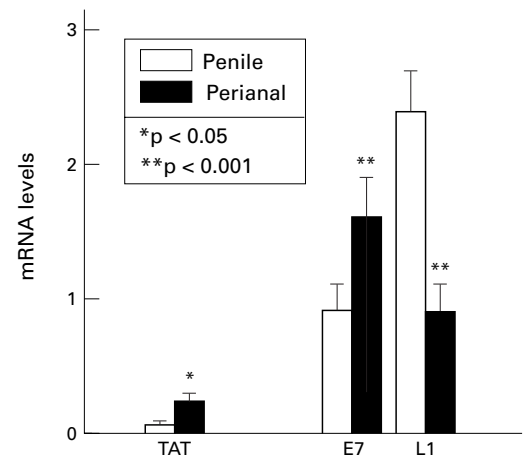


Figure 3 Expression of HIV-tat and HPV early (E7) and late (L1) genes in penile and perianal condyloma biopsies from HIV positive individuals. HIV-tat as well as HPV early (E7) and late (L1) transcripts were determined by RT-PCR in RNAs isolated from penile or perianal condylomas as seen in figure 2. mRNA levels were expressed as ratios of target gene normalised to G3PDH. Data are given as mean (SD) (n=8).

NUCLEIC ACID ISOLATION

DNA and RNA were simultaneously isolated from frozen specimens using Tri-Reagent (Molecular Research Center, Inc, Cincinnati, OH, USA) as described earlier.¹⁰

DETECTION AND TYPING OF HPV

Presence of HPV in tissue DNAs was confirmed by polymerase chain reaction (PCR) using consensus L1 primer pairs.¹⁸ HPV types were determined by direct sequencing of the L1-PCR fragments as described elsewhere.¹⁹ Alternatively, L1-PCR fragments were hybridised by a slot blot technique using labelled type specific probes.^{18 19}

SEMIQUANTITATION OF MRNAS BY RT-PCR

RNAs were reverse transcribed using random hexamers (Promega) and Superscript II reverse transcriptase (Gibco/BRL). The resulting cDNAs were subjected to PCR amplification using specific primer pairs together with an internal control gene (G3PDH: glyceraldehyde-3-phosphate-dehydrogenase) as described earlier.¹⁰ G3PDH served as a constitutively expressed internal control gene to normalise uneven cDNA loads and demonstrate integrity of RNAs. Primers were designed and synthesised, as previously reported.²⁰ The sizes of gene specific PCR fragments are as follows: G3PDH

(452 bp), INV (involucrin: 394 bp), Tgase (keratinocyte transglutaminase: 400 bp), K10 (keratin 10: 659 bp), K16 (keratin 16: 357 bp), K17 (keratin 17: 400 bp), VIM (vimentin: 399 bp), PCNA (proliferating cell nuclear antigen: 418 bp), c-myc (479 bp), HIV-tat (132 bp), HPV6-E7 (306 bp), HPV11-E7 (248 bp), HPV6-L1 (440 bp), HPV11-L1 (401 bp), HLA-B7 (718 bp), HLA-DR β (280 bp), CD1a (Langerhans cell: 424 bp), CD16 (macrophage/NK cell: 332 bp), CD4 (helper T cell: 438 bp), and CD8 (cytotoxic T cell: 454 bp). PCR fragments were resolved in 1.5% agarose gel by electrophoresis and transferred to a nylon membrane (Amersham) by semi-dry transfer system (BioRad). Membranes were hybridised with end labelled type specific probes and autoradiographed. Autoradiograms were evaluated by densitometry (Alpha Innotech). mRNA levels were given as ratios to the internal control gene G3PDH.

STATISTICAL ANALYSIS

Data were analysed by linear regression and Student's *t* test using SIGMASTAT statistical software (Jandel).

Results

HPV TYPES IN DIFFERENT BIOPSIES

Perianal and penile biopsies exhibited double HPV infection: in each biopsy we demonstrated the presence of HPV types 6 plus 11 (data not shown). Condylomas usually contain single infection of HPV 6 or 11.^{21 22} However, under immunosuppression multiple infection frequently occurs.²³ Our observation is in agreement with those results. Biopsies, which originated from patients with CD4 counts less than 300 also contained oncogenic HPV types,^{24 25} such as types 16 and 18, but in low copy numbers.²⁶ In these experiments, we exclusively used those biopsies that contained only the non-oncogenic types—that is, patients with CD4 counts >300.

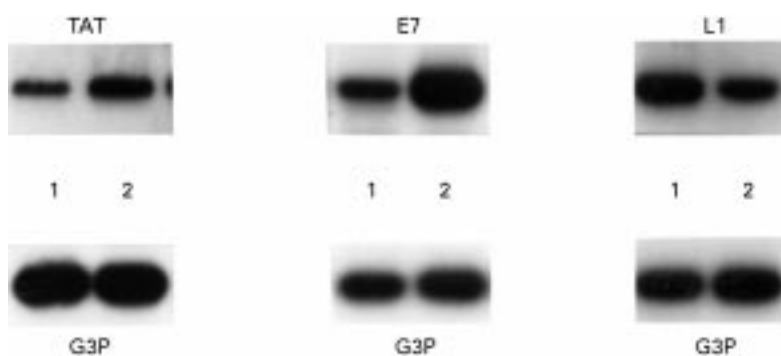


Figure 2 Representative RT-PCR result on HIV and HPV transcripts. (TAT) HIV-tat, (E7), HPV E7 and (L1) HPV L1 messages were amplified in cDNA from a penile (1) and a perianal condyloma (2) by PCR using gene specific primer pairs. Also, G3PDH was amplified from the same cDNAs to demonstrate RNA integrity and equal cDNA load.

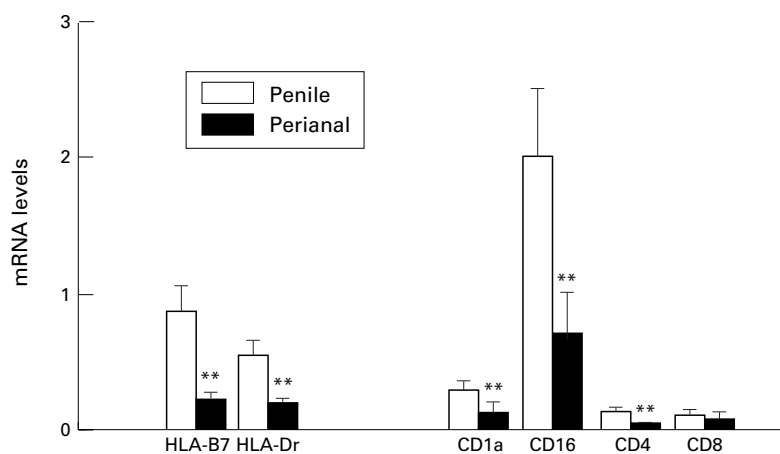


Figure 4 Status of local immunity in penile and perianal condyloma biopsies from HIV positive individuals. mRNA levels of antigen presentation and recognition molecules (HLA-B7 = MHC class I; HLA-DR = MHC class II; CD1a = Langerhans cells; CD16 = macrophages/NK cells; CD4 = helper T cells; and CD8 = cytotoxic T cells) were determined by RT-PCR. mRNA levels were expressed as ratios of target gene normalised to G3PDH. Data are given as mean (SD) (n=8).

STATUS OF PROLIFERATION AND DIFFERENTIATION IN PENILE AND PERIANAL BIOPSIES

mRNA levels of tissue differentiation markers²⁷ such as involucrin (INV), keratinocyte transglutaminase (TGase), and keratin 10 (K10) were determined along with proliferation markers²⁸⁻³⁰ such as proliferating cell nuclear antigen (PCNA), c-myc, and keratins 16 (K16) and 17 (K17) (fig 1). As shown, perianal biopsies expressed lower levels of differentiation markers, but PCNA and c-myc, as well as K16 and K17 were significantly higher in perianal tissues. Vimentin (VIM), a marker of dermal tissues,³¹ was used to demonstrate equal epidermis/dermis ratios in biopsies.

EXPRESSION OF VIRAL GENES

mRNA levels of HPV early (E7) and late (L1) genes as well as HIV-tat gene were determined by RT-PCR (figs 2, 3). Interestingly, perianal tissues preferentially expressed HPV E7 transcripts while penile tissues mainly expressed L1 products. Owing to the multiple HPV infection, HPV E7 and HPV L1 levels are the sum

of HPV 6 and HPV 11 E7 and L1 levels. HIV-tat expression was greater in perianal tissues.

STATUS OF LOCAL IMMUNITY IN BIOPSIES

There were significant differences in local immune factors between penile and perianal specimens (fig 4). There was a significant depletion in Langerhans cells (CD1a) and CD4 positive T lymphocytes in the perianal tissues. Also, perianal tissues were less infiltrated by macrophages (CD16) than penile tissues. Surface molecules of antigen presentation such as MHC class I (HLA-B7) and MHC class II (HLA-DR) were also downregulated in perianal biopsies relative to penile tissue.

CORRELATION BETWEEN HIV-TAT AND HPV E7

LEVELS AS WELL AS LOCAL IMMUNOSUPPRESSION
HIV-tat levels positively correlated with HPV E7 levels and negatively with L1 (data not shown) in all biopsies (fig 5A). However, this correlation significantly differed between penile and perianal tissues; perianal biopsies exhibited higher HIV-tat related HPV E7 (see also fig 3). On the other hand, HPV E7 levels negatively correlated with CD1a levels (Langerhans cells) (fig 5B). A significantly higher HPV E7 related depletion of CD1a was observed in perianal specimens.

Discussion

Evidence from immunosuppressed individuals strongly suggests that the immune system is important in the pathogenesis of HPV induced disease.³² Studies on spontaneous or treatment induced regressing genital warts demonstrated that cell mediated immune responses are important in clearance of wart tissues in which TH-1 type lymphocytes and macrophages predominate.^{20 33} However, there is little knowledge on interactions between the local immune system and the infecting HPV. Studies suggest a direct interaction between HPV E5 gene and MHC molecules.³⁴ Other studies found a negative correlation between Langerhans cell content and HPV replication³⁵ or HPV E7 levels.⁹ Also, HPV infected cells express significantly lower

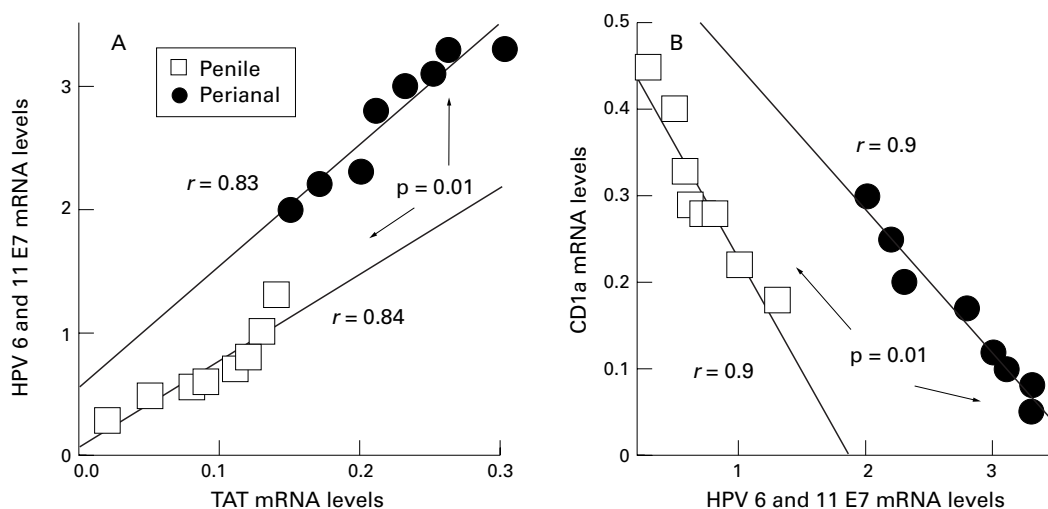


Figure 5 Association between HIV-tat and HPV E7 (A) as well as between HPV E7 and CD1a mRNA levels in penile and perianal condyloma biopsies from HIV positive individuals. (A) HIV-tat and HPV E7 mRNA levels were determined by RT-PCR in biopsies of penile and perianal condylomas. Linear regression was done using SIGMASTAT statistical software. (B) HPV E7 mRNA levels were also compared with Langerhans cell (CD1a) mRNA content.

amounts of pro-inflammatory cytokines.^{7 8} Therefore, either directly or indirectly, HPV transcription is an important factor in influencing the status of local immunity. HPVs express different sets of genes, some of them termed "early" genes. These early genes, such as E6 and E7 are responsible for many of HPV related alterations in the infected cell.³⁶ Their expression is tightly coupled to cellular differentiation.^{37 38} We also demonstrated that tissue specific differentiation characterised by expression of various keratins allows differential transcription of HPV early and late genes.¹⁰ We also demonstrated that this differential HPV expression is associated with altered responses to cytokine therapies¹⁰ and local immune responses.^{9 20}

Perianal skin comprises keratinised squamous epithelia with skin appendages³⁹ expressing keratins of stratified squamous epithelia (such as K1, 10, 5, 14) and keratins of incomplete differentiation (such as K16) as well as keratins of complex epithelia (such as K17).⁴⁰ In contrast, penile skin expresses keratins of orthokeratotic epidermis, such as K1, K10, K5, and K14.⁴¹ These differences imply different stages of cellular differentiation, as perianal skin exhibits signs of incomplete differentiation and more proliferative property (K16). Tumours of a particular epithelium tend to retain their basic keratinisation profile of their tissue origin modified by the transformation process.⁴² Indeed, mRNA levels of markers of epithelial differentiation such as keratins, involucrin (INV) and keratinocyte transglutaminase (TGase) differ between penile and perianal biopsies (fig 1). Taken together with markers of proliferation such as PCNA and *c-myc*, perianal biopsies appear more proliferative while penile biopsies are more differentiated.

According to their keratinisation pattern, those biopsies contain different amounts of HPV-RNA species (fig 3). The more differentiated penile epithelium preferentially expresses HPV late (L1) message, while the more proliferative perianal epithelium preferentially contains HPV early (E7) message. This phenomenon is similar to that described in IFN responsive and resistant condylomas.¹⁰

Interestingly, markers of local immunity were also significantly different between those tissues (fig 4). mRNA levels of surface molecules such as MHC class I and II (HLA-B7 and HLA-DR, respectively) were significantly lower in perianal skin. Also, major constituents of skin immune responses, the Langerhans cells,⁴³ were more significantly depleted in perianal biopsies relative to penile tissue.⁴⁴ Of course, we cannot exclude the possibility that perianal tissues normally contain lower levels of Langerhans cells, since rectal epithelia contain very low numbers of Langerhans cells.⁴⁵ Since Langerhans cells constitutively express HLA-DR,^{46 47} the observed decrease in HLA-DR might correlate with depletion of Langerhans cells. Another possibility is that the Langerhans cell content is unchanged but its HLA-DR transcriptional machinery is impaired. MHC class II molecules present antigen to CD4 positive T cell

populations. Evidently, the observed CD4 lymphocyte depletion might be associated with the lack of MHC II. CD8 lymphocytes receive signals through MHC I molecules. There was no difference in CD8 levels between perianal and penile epithelia, even though perianal epithelium expressed lower amounts of HLA-B7. Also, markers of macrophages/NK cells (CD16) demonstrated lower levels in perianal biopsies. Therefore, perianal lesions may mount lower levels of immune responses than do penile lesions.

HIV-*tat* mRNA was demonstrable in every biopsy; however, perianal biopsies contained greater amounts (fig 3), even though Langerhans cell, macrophage, and CD4 T cell contents of perianal biopsies were lower (fig 4). These cell types are believed to be carriers of HIV in the skin.⁴⁸ Since vimentin levels were identical in both biopsy groups (fig 1) we could also rule out the possibility of uneven biopsies that could lead to different levels of cells in the dermal section. This finding represents a more favourable HIV-*tat* expression in perianal epithelia.

It is believed that HIV-*tat* is able to alter cellular cytokine expression⁴⁹ and transactivate the HPV promoter.^{50 51} The other possibility is that the impaired lymphocyte function in HIV infection allows the HPV infection to progress.¹¹ In our cases, HIV-*tat* mRNA levels positively correlated with HPV E7 levels (fig 5A). Also, perianal biopsies contained significantly higher levels of both HIV-*tat* and HPV E7 (see also fig 3). In addition, the higher HPV E7 levels negatively correlated with Langerhans cell content (fig 5B), but with significant differences between perianal and penile lesions. We can conclude that HIV-*tat* might have a role in upregulating HPV E7 levels that consequently leads to local immunodeficiency by depleting Langerhans cells and other effectors of the local immunity.

Conclusions

Differentiation properties of the perianal epithelium are different from the epithelium of the penile shaft. These differences determine the expression pattern of HPV, as the perianal epithelium shifts the HPV expression to the early genes. HIV infection might activate HPV early genes also in a tissue specific manner, favouring the perianal epithelia. Consequently, the perineum may mount lower immune responses against HPV infection since it is more depleted in immune presenting cells such as Langerhans cells, CD4 T cells, and macrophages. This local immunodeficiency may account for the higher rate of HPV occurrence in the perianal area than in the penile shaft both in HIV negative and HIV positive individuals.⁵¹ These data also might explain the more aggressive and less curable properties of perianal lesions. Our conclusion is based on the assumption that specific mRNA species are probably produced by specific cell types. However, morphological correlation is necessary to further support these observations.

- 1 Zur Hausen H. Papillomavirus infections—a major cause of human cancers. *Biochim Biophys Acta* 1996;1288:F55–78.
- 2 Schneider A. Pathogenesis of genital HPV infection. *Gentiourin Med* 1993;69:165–73.
- 3 Viac J, Chardonnet Y, Euvrard S, et al. Langerhans cells, inflammation markers and human papillomavirus infections in benign and malignant epithelial tumors from transplant recipients. *J Dermatol* 1992;19:67–77.
- 4 Viac J, Soler C, Chardonnet Y, et al. Expression of immune associated surface antigens of keratinocytes in human papillomavirus-derived lesions. *Immunobiol* 1993;188:392–402.
- 5 Connor ME, Stern PL. Loss of MHC class-I expression in cervical carcinomas. *Int J Cancer* 1990;46:1029–34.
- 6 Altmann A, Jochmus I, Rosl F. Intra- and extracellular control mechanisms of human papillomavirus infection. *Inter-virology* 1994;37:180–8.
- 7 Arany I, Rady P, Tyring SK. Alterations in cytokine/anti-oncogene expression in skin lesions caused by “low risk” types of human papillomaviruses. *Viral Immunol* 1993;6:255–65.
- 8 Woodworth CD, Simpson S. Comparative lymphokine secretion by cultured normal human cervical keratinocytes, papillomavirus-immortalized, and carcinoma cell lines. *Am J Pathol* 1993;142:1544–55.
- 9 Arany I, Tyring SK. Status of local cellular immunity in interferon responsive and nonresponsive human papillomavirus-associated lesions. *Sex Transm Dis* 1996;26:475–80.
- 10 Arany I, Brysk MM, Brysk H, Tyring SK. Response to interferon treatment decreases with epidermal dedifferentiation in condylomas. *Antivir Res* 1996;32:19–26.
- 11 Braun L. Role of human immunodeficiency virus infection in the pathogenesis of human papillomavirus-associated cervical neoplasia. *Am J Pathol* 1994;144:209–14.
- 12 Matorras R, Aricte JM, Rementaria A, et al. Human immunodeficiency virus-induced immunosuppression: a risk factor for human papillomavirus infection. *Am J Obstet Gynecol* 1991;164:42–4.
- 13 Chirgwin KD, Feldman J, Augenbraun M, et al. Incidence of venereal warts in human immunodeficiency virus-infected and uninfected women. *J Infect Dis* 1995;172:235–8.
- 14 Schafer A, Friedmann W, Mielke M, et al. The increased frequency of cervical dysplasia-neoplasia in women infected with the human immunodeficiency virus is related to the degree of immunosuppression. *Am J Obstet Gynecol* 1991;164:593–9.
- 15 Johnson JC, Burnett AF, Willet GD, et al. High frequency of latent and clinical human papillomavirus cervical infection in immunocompromised human immunodeficiency virus-infected women. *Obstet Gynecol* 1992;79:321–7.
- 16 Feingold AR, Vermund SH, Burk RD, et al. Cervical cytologic abnormalities and papillomavirus in women infected with human immunodeficiency virus. *J Acquir Defic Syndr* 1990;3:896–903.
- 17 Vermund SH, Kelley KF, Klein RS, et al. High risk of human papillomavirus infection and cervical squamous intraepithelial lesions among women with symptomatic human immunodeficiency virus infection. *Am J Obstet Gynecol* 1991;165:392–400.
- 18 Resnick RM, Cornelissen MTE, Wright DK, et al. Detection and typing of human papillomavirus in archival cervical cancer specimens by DNA amplification with consensus primers. *J Natl Cancer Inst* 1990;82:1477–1484.
- 19 Rady P, Arany I, Hughes TK, et al. Type-specific primer-mediated direct sequencing of consensus primer-generated PCR amplicons of human papilloma viruses: a new approach for the simultaneous detection of multiple viral type infections. *J Virol Methods* 1995;53:245–54.
- 20 Arany I, Tyring SK. Activation of local cell-mediated immunity in interferon responsive patients with human papillomavirus-associated lesions. *J Interferon Cytokine Res* 1996;16:453–60.
- 21 Beckmann AM, Sherman KJ, Myerson D, et al. Comparative virologic studies of condylomata acuminata reveal a lack of dual infections with human papillomaviruses. *J Infect Dis* 1991;163:393–6.
- 22 Brown DR, Fife KH. Human papillomavirus infections of the genital tract. *Med Clin N Am* 1990;74:1455–85.
- 23 Brown DR, Bryan JT, Cramer H, et al. Detection of multiple human papillomavirus types in condylomata acuminata from immunosuppressed patients. *J Infect Dis* 1994;170:759–65.
- 24 Caussy D, Goedert JJ, Palefsky J, et al. Interaction of human immunodeficiency and papilloma viruses: association with anal epithelial abnormality in homosexual men. *Int J Cancer* 1990;46:214–19.
- 25 Melbye M, Palefsky J, Gonzales J, et al. Immune status as a determinant of human papillomavirus detection and its association with anal epithelial abnormalities. *Int J Cancer* 1990;46:203–6.
- 26 Arany I, Tyring SK. Systemic immunosuppression by HIV infection influences HPV transcription and thus local immune responses in condylomas. *Int J AIDS STD* 1998;9:268–71.
- 27 Fuchs E. Epidermal differentiation: the bare essentials. *J Cell Biol* 1990;111:2807–14.
- 28 Barker JNWN, Goodlad JR, Ross EL, et al. Increased epidermal cell proliferation in normal human skin in vivo following local administration of interferon- γ . *Am J Pathol* 1993;142:1091–7.
- 29 Roberts JM. Turning DNA replication on and off. *Curr Opin Cell Biol* 1993;5:201–6.
- 30 Waga S, Hannon GJ, Beach D, et al. The p21 inhibitor of cyclin-dependent kinases controls DNA replication by interaction with PCNA. *Nature* 1994;369:574–8.
- 31 Leader M, Collins M, Patel J, et al. Vimentin: an evaluation of its role as a tumour marker. *Histopathology* 1987;11:63–72.
- 32 Coleman N, Birley HDL, Renton AM, et al. Immunological events in regressing genital warts. *Am J Clin Pathol* 1994;102:768–74.
- 33 McFadden G, Kane K. How DNA viruses perturb functional MHC expression to alter immune recognition. *Adv Cancer Res* 1994;63:117–209.
- 34 Lehtinen M, Rantala I, Toivonen A, et al. Depletion of Langerhans cells in cervical HPV infection is associated with replication of the virus. *APMIS* 1993;101:833–7.
- 35 Munger K, Phelps WC. The human papillomavirus E7 protein as a transforming and transactivating factor. *Biochim Biophys Acta* 1993;1155:111–23.
- 36 Iftner T, Oft M, Bohm S, et al. Transcription of the E6 and E7 genes of human papillomavirus type 6 in anogenital condylomata is restricted to undifferentiated cell layers of the epithelium. *J Virol* 1992;66:4639–46.
- 37 Stoler MH, Wolinsky SM, Whitbeck A, et al. Differentiation-linked human papillomavirus types 6 and 11 transcription in genital condylomata revealed by in situ hybridization with message-specific RNA probes. *Virology* 1989;172:331–40.
- 38 Fenger C. Histology of the anal canal. *Am J Surg Pathol* 1988;12:41–55.
- 39 Williams GR, Talbot IC, Northover JM, et al. Keratin expression in the normal anal canal. *Histopathology* 1995;26:39–44.
- 40 Moll R, Franke WW, Schiller DL, et al. The catalog of human cytokeratins: patterns of expression in normal epithelia, tumors and cultured cells. *Cell* 1982;31:11–24.
- 41 Kim KH, Schwartz F, Fuchs E. Differences in keratin synthesis between normal epithelial cells and squamous cell carcinomas are mediated by vitamin A. *Proc Natl Acad Sci USA* 1984;81:4280–4.
- 42 Memar O, Arany I, Tyring SK. Skin associated lymphoid tissue in HIV-1, HPV and HSV infections. *J Invest Dermatol* 1995;105:995–1045.
- 43 Muller H, Weier S, Kojouharoff G, et al. Distribution and infection of Langerhans cells in the skin of HIV-infected healthy subjects and AIDS patients. *Res Virol* 1993;144:59–67.
- 44 Hussain LA, Lehner T. Comparative investigation of Langerhans' cells and potential receptors for HIV in oral, genitourinary and rectal epithelia. *Immunology* 1995;85:475–84.
- 45 Cruz PD, Bergstresser PR. Antigen processing and presentation by epidermal Langerhans cells. Induction of immunity or unresponsiveness. *Dermatol Clin* 1991;9:633–47.
- 46 Hughes RG, Norval M, Howie SEM. Expression of major histocompatibility class II antigens by Langerhans' cells in cervical intraepithelial neoplasia. *J Clin Pathol* 1988;41:253–9.
- 47 Blauvelt A, Katz SI. The skin as target, vector, and effector organ in human immunodeficiency virus disease. *J Invest Dermatol* 1995;105:1225–65.
- 48 Chang H-K, Gallo RC, Ensoli B. Regulation of cellular gene expression and function by the human immunodeficiency virus type 1 tat protein. *J Biomed Sci* 1995;2:189–202.
- 49 Tornesello ML, Buonaguro FM, Beth-Giraldo E, et al. Human immunodeficiency virus type 1 tat gene enhances human papillomavirus early gene expression. *Intervirology* 1993;36:57–64.
- 50 Vernon SD, Hart CE, Reeves WC, et al. The HIV-1 tat protein enhances E2-dependent human papillomavirus 16 transcription. *Virus Res* 1993;27:133–45.
- 51 Breese PL, Judson FN, Penley KA, et al. Anal human papillomavirus infection among homosexual and bisexual men: prevalence of type-specific infection and association with human immunodeficiency virus. *Sex Transm Dis* 1995;22:7–14.



Tissue specific HPV expression and downregulation of local immune responses in condylomas from HIV seropositive individuals.

I Arany, T Evans and S K Tyring

Sex Transm Infect 1998 74: 349-353

doi: 10.1136/sti.74.5.349

Updated information and services can be found at:

<http://sti.bmj.com/content/74/5/349>

References

These include:

Article cited in:

<http://sti.bmj.com/content/74/5/349#related-urls>

Email alerting service

Receive free email alerts when new articles cite this article. Sign up in the box at the top right corner of the online article.

Notes

To request permissions go to:

<http://group.bmj.com/group/rights-licensing/permissions>

To order reprints go to:

<http://journals.bmj.com/cgi/reprintform>

To subscribe to BMJ go to:

<http://group.bmj.com/subscribe/>