

We therefore recommend that patients suffering from acute intermittent porphyria and requiring treatment for chlamydial infection are prescribed doxycycline with the proviso that urinary porphyrin concentrations are measured before and after treatment. This will also allow improvement of the Porphyrin Laboratory Data Bank.

Yours faithfully,
J R Smith
S M Forster

Academic Department of
Genitourinary Medicine,
St Mary's Hospital, London W2

Reference

- Schachter J. Biology of *Chlamydia trachomatis*. In: Holmes KK, Mårdh P-A, Sparling PF, Weisener PJ, eds. *Sexually transmitted diseases*. New York: McGraw Hill, 1984: 249-50.

TO THE EDITOR, *Genitourinary Medicine*

Electron microscopy to differentiate intestinal spirochaetosis from other conditions

Sir,

Intestinal spirochaetosis is present in up to 6.9% of hospital patients undergoing rectal biopsy, and a prevalence of over 30% has been reported in homosexual men.¹ Although its pathological importance is not certain, various clinical symptoms have been ascribed to infestation of the gastrointestinal tract with spirochaetes. These include diarrhoea, rectal discharge, and pain on defaecation. Sigmoidoscopic examination may or may not show normal appearances. The condition is recognised on light microscopy by the presence of a haematoxyphilic band coating the surface of the rectal mucosa. We report a case in which a similar basophilic band was present, but which was not due to spirochaetosis.

A man aged 72 presented with a six week history of diarrhoea that began one week after his return from Spain. He had had no homosexual contact. Physical examination was unremarkable, and sigmoidoscopic appearances were normal. Examination of a rectal biopsy specimen (fig, top) showed normal mucosal architecture and no evidence of inflammation. However, a basophilic band was present at the brush border of the mucosal surface, and the possibility of intestinal spirochaetosis was considered. Transmission electron microscopy of further material from the residual tissue in the paraffin block showed that the cause of the basophilic band was a dense layer of mucus attached to the surface of the brush border, and showed no evidence of

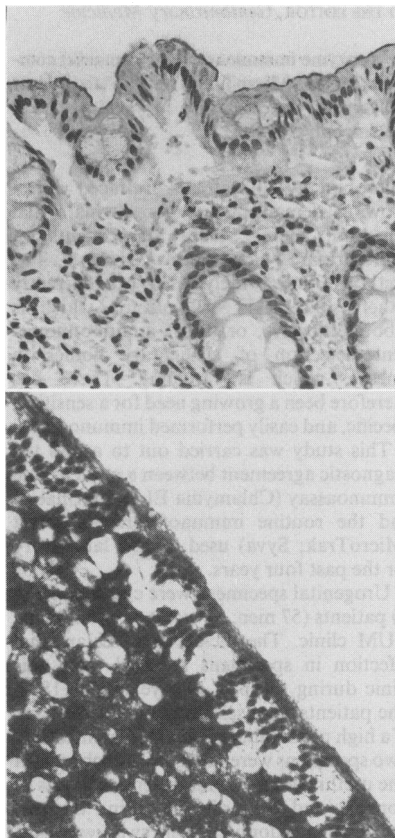


Figure (top) Rectal mucosa with basophilic band at the brush border, an appearance similar to that seen in intestinal spirochaetosis. Electron micrograph (bottom) of surface of rectal mucosa showing dense layer of mucus on surface of the brush border. Normal numbers of microvilli present beneath mucus layer.

spirochaetes (fig, bottom). No other organism was identified.

Though the presence of a basophilic band in a rectal mucosal biopsy specimen should alert the pathologist to the possibility of spirochaetosis, this case illustrates the fact that a similar appearance may be produced by other causes. The basophilic band in this case was slightly thinner than that normally associated with spirochaetosis, and individual spirochaetes could not be shown convincingly using the 100 x objective. Though these subtle differences may help in diagnosis, electron microscopy remains the final arbiter.

Yours faithfully,
K M Roberts
D W K Cotton
J R Shortland

Department of Pathology,
University of Sheffield Medical School,
Beech Hill Road, Sheffield S10 2RX

Reference

- Cooper C, Cotton DWK, Hudson MJ, Kirkham N, Wilmott FEW. Rectal spirochaetosis in homosexual men: characterisation of the organism and pathophysiology. *Genitourin Med* 1986;62:47-52.

TO THE EDITOR, *Genitourinary Medicine*

Trichomonal vaginitis refractory to conventional treatment

Sir,

Recent reports in *Genitourinary Medicine*¹⁻³ have highlighted the difficulties in managing trichomonal vaginitis when conventional treatment with metronidazole has failed. There is a place for more aggressive treatment than suggested.

Metronidazole is well absorbed in the absence of gastrointestinal diseases and should be given by mouth rather than intravenously unless the patient is vomiting. It can safely be given by mouth in doses of up to 3 g a day for 14 days, but doses exceeding 4 g a day for 14 days have produced peripheral neuropathy, which may be prolonged and disabling.⁴

Two women seen recently have been cured only by high dose treatment. One, who had been given 17 different courses of treatment during two and half years without success, responded to oral metronidazole 3 g a day by mouth in divided doses and 1 g vaginally at night for 18 days. The second, similar, patient was cured by the same regimen, but for 14 days.

Two points seem worthy of emphasis. Firstly, the difficulty that many of us have in getting sensitivity tests performed on trichomonads that appear clinically to be resistant to metronidazole. Facilities for sensitivity testing using an acceptable standard method need to be made more easily available.⁵ Secondly, vaccination has proved useful in the prophylaxis of recurrent trichomoniasis, although not in treating resistant organisms. In discussing its mode of action we should eschew references to "aberrant" and "different" strains of *Lactobacillus acidophilus*.⁶ Such terms do not accord with modern microbiological concepts.⁷

Yours faithfully,
S A Seligman

Correspondence

Department of Obstetrics and Gynaecology,
Luton and Dunstable Hospital,
Luton, Bedfordshire

References

- Ahmed-Jushuf IH, Murray AE, McKeown J. Managing trichomonal vaginitis refractory to conventional treatment with metronidazole. *Genitourin Med* 1988;64:25-9.
- Lumsden WHR, Robertson DHH, Heyworth R, Harrison C. Treatment failure in *Trichomonas vaginalis* vaginitis. *Genitourin Med* 1988;64:217-8.
- Sprott MS, Kearns AM, Pattman RS. Trichomonal vaginitis refractory to treatment: case report. *Genitourin Med* 1988;64:369-72.
- Lossick JG, Müller M, Gorrell TE. In vitro drug susceptibility and doses of metronidazole required for cure in cases of refractory vaginal trichomoniasis. *J Infect Dis* 1986;153:948-55.
- Lumsden WHR, Harrison C, Robertson DHH. Treatment failure in *Trichomonas vaginalis* infection in females. 2. In vitro estimation of the sensitivity of the organism to metronidazole. *J Antimicrob Chemother* 1988;21:555-64.
- Milovanović R, Grčić R, Stojković L. Serological study with SolcoTrichovac, a vaccine against *Trichomonas vaginalis* in women. *Gynäkol Rundsch* 1982;22suppl 2:39-45.
- Seligman SA, Stannard AJ, Willis AT. Vaginal lactobacilli. *J Obstet Gynaecol* 1986;6suppl 1:47-9.

TO THE EDITOR, *Genitourinary Medicine*

Mystery of the holey prepuce: delayed podophyllin skin damage?

Sir,
A West Indian man aged 24 attended the genitourinary medicine clinic at the Manchester Royal Infirmary in July 1988 with a recurrence of penile warts. He had been treated at the clinic once before, from December 1985 to August 1986, for genital warts and non-gonococcal urethritis. In 1986, while being treated for warts with 25% podophyllin in glycerol, he had developed a local reaction to podophyllin which had resulted in skin erosions on the foreskin. Podophyllin treatment had been discontinued immediately, and the skin erosions had been treated by using saline baths and giving co-trimoxazole tablets for five days. The skin had healed satisfactorily and the warts had disappeared before he was discharged in August 1986.

When he attended again in July 1988, he was found to have a large hyperkeratotic wart on the foreskin and a large (18 mm in diameter) well healed circular hole on the

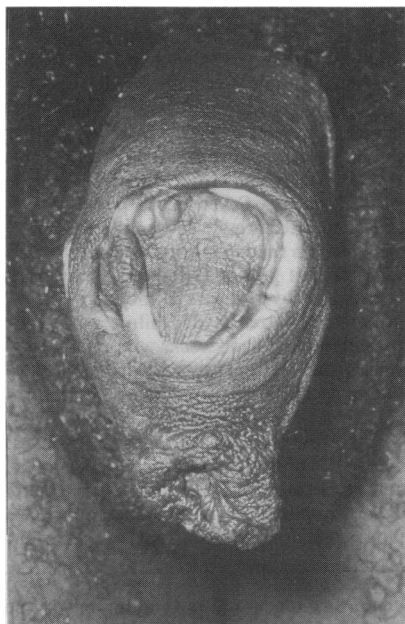

Figure Circular hole (18 mm in diameter) in dorsal aspect of foreskin.

dorsal aspect of the foreskin—like a round window (fig). No evidence of any other sexually transmitted disease was found. When questioned about the hole in the foreskin, he replied that it had developed seven to eight months after the podophyllin reaction that he had experienced in August 1986. He said that he had not treated himself in any way or received treatment elsewhere during the intervening two years. He had abstained from sexual intercourse for the previous 12 months. His wart was removed with cryotherapy, and he was referred to a surgeon for circumcision for cosmetic reasons.

The interesting features that attracted our attention to this case were, firstly, the patient's lack of concern about the obvious foreskin deformity, and, secondly, the long interval (seven to eight months) between the recorded podophyllin reaction in August 1986 and the appearance of the hole in the foreskin, especially as he had had no ulceration and the skin had healed satisfactorily when he had been discharged from the clinic in 1986. His lack of concern about the obvious deformity of the foreskin made us think that this possibly could have been the result of either self treatment or treatment he had received elsewhere, which is of course difficult to prove.

We were unable to find any record of delayed podophyllin damage, although local

immediate reactions are common.¹⁻³ The hole in the prepuce remains a mystery to us, and we would be interested to know if anyone else has experienced this type of delayed reaction to podophyllin.

Yours faithfully,

H Maiti

K R Haye

Department of Genitourinary Medicine,
Manchester Royal Infirmary, M13 9WL

References

- Sullivan M, King L. Effects of resin of podophyllin on normal skin, condylomata acuminata and verrucae vulgaris. *Archives of Dermatology and Syphilology* 1947;56:30-47.
- Adler MW. *ABC of sexually transmitted diseases*. 2nd ed. London: BMJ, 1985:30.
- Maiti H, Haye KR. Self-treatment of condylomata acuminata with podophyllin resin. *Practitioner* 1985;229:37-9.

TO THE EDITOR, *Genitourinary Medicine*

Econazole nitrate (150 mg) single dose vaginal pessary compared with clotrimazole (10%) single dose vaginal cream to treat women with vaginal candidiasis

Sir,

We undertook an open study to assess the efficacy and acceptability to patients of two imidazole antifungal compounds used vaginally in vulvovaginal candidiasis. We studied 120 women patients with symptoms of vaginal discharge or itching, or both, who yielded *Candida* spp from high vaginal swabs. We excluded patients with concomitant gonorrhoea, trichomoniasis, or bacterial vaginosis or who required vulval topical treatments. We recorded the presence and duration of symptoms and signs before and two and four weeks after treatment.

Table Clinical and mycological efficacy* of econazole and clotrimazole to treat 82 women with vulvovaginal candidiasis (figures are numbers (percentages) of women)

	Econazole	Clotrimazole
Short term efficacy:	(n = 43)	(n = 39)
Clinical	31 (72)	29 (74)
Mycological	32 (74)	29 (74)
Long term efficacy:	(n = 31)	(n = 27)
Clinical	24 (77)	17 (63)
Mycological	26 (84)	18 (67)

*Clinical efficacy = resolution of symptoms and signs, mycological efficacy = no growth of *Candida* spp.