

Guinea worm inguinal adenopathy

A. O. OSOBA AND A. B. O. OYEDIRAN

Departments of Medical Microbiology and Preventive and Social Medicine, University of Ibadan, Ibadan, Nigeria

SUMMARY Genital involvement of *Dracunculus medinensis* is uncommon, and when it does occur, it usually involves the scrotum. A case has been described in which the inguinal gland was involved producing a bubo simulating that caused by other commoner conditions. It is suggested that the microscopical examination of a wet preparation of bubo aspirates should routinely be practised, especially in tropical countries.

Introduction

Guinea worm (*Dracunculus medinensis*) is found in many parts of Africa and India (Manson-Bahr, 1966). The female worm measures about 32.5 cm to 120 cm in length by 1 to 5 mm in diameter, while the male is very much smaller and rarely seen. The embryos are somewhat flattened with a tapering tail and measure 0.5 to 0.75 mm in length by 0.017 mm in breadth.

The guinea worm on reaching maturity usually finds its way to the lower limbs, being the parts of the body that most frequently come into contact with water in wells and ponds. It is in these locations that Cyclops, the intermediate hosts, are usually found. The adult female guinea worm has a predilection for the connective tissue of the limbs and trunk. The mature worm burrows her way through the tissues of the extremities. In 85% of cases she presents in some part of the lower extremities, occasionally in the scrotum (Willcox, 1964), or the dorsum or sole of the foot, rarely in the arms; exceptionally she burrows in other parts of the body including the head (Manson-Bahr, 1966).

We are reporting this case because of its unusual presentation and location in the inguinal glands, simulating the common causes of inguinal adenitis, in order to alert physicians, particularly in tropical countries.

Material and methods

CASE REPORT

A 22-year-old Nigerian male labourer presented at the Endemic Diseases Clinic of the University College Hospital, Ibadan, complaining of two painful

swellings in the right groin of three weeks' duration. His last sexual exposure had been six months previously.

On examination, he had two large swellings in the right groin separated by a marked groove. The masses were not tender and the lower mass was beginning to point but no vesicle was present. A few small shotty glands were palpable in the left groin. He had no evidence of penile ulceration and his external genitalia were otherwise normal. He had no urethral discharge and his two-glass urine test was normal. He was afebrile. He had no generalised symptoms of toxic or allergic nature. A provisional diagnosis of acute lymphogranuloma venereum inguinal bubo was made, and he was asked to attend for aspiration of the bubo, while awaiting the results of the investigations.

INVESTIGATIONS AND RESULTS

Total WBC were $5 \times 10^9/l$. Results of Heaf test, Venereal Disease Reference Laboratory (VDRL) test, Fluorescent Treponemal Antibody 200 test, and Frei test were all negative. The lymphogranuloma venereum complement fixation test was positive at a titre of 1:4, but a radiograph of the right leg showed no abnormality of bone or soft tissue.

When the patient was seen 48 hours after his first visit, he reported spontaneous rupture of the lower inguinal swelling with a guinea worm measuring about 8 cm protruding from the ulcer (Figure).

Microscopical examination of a wet preparation of the aspirated pus revealed numerous guinea worm larvae and pus cells. Culture of the aspirated bubo pus did not grow any pathogens and the Ziehl-Nielsen stain of the pus did not reveal any acid-fast bacilli.

The patient was treated with niridazole (Ambilhar) 750 mg in the morning and 500 mg in the evening for 10 days. To prevent any minor side-effects that are sometimes encountered with the drug, promethazine

Address for reprints: Dr A. O. Osoba, Senior Lecturer and Consultant, Special Treatment Clinic, University of Ibadan, Department of Medical Microbiology, University College Hospital, Ibadan, Nigeria

Received for publication 18 March 1976

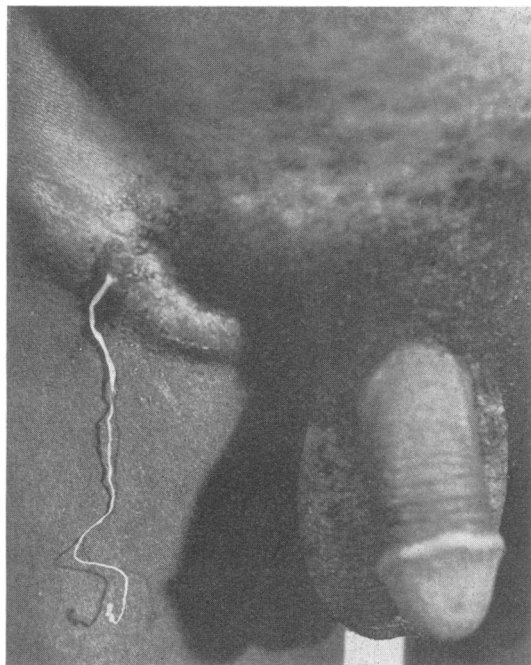


Figure Guinea worm emerging from the right inguinal bubo.

hydrochloride (Phenergan) 10 mg twice daily was also prescribed.

After two days of this treatment the worm was expelled. By completion of the treatment the inguinal ulcer had healed and the swellings in the right groin disappeared. When the patient was seen a month later, he complained of a slight discomfort in the right leg, which showed cord-like thickening on the medial aspect of the lower leg. This was thought to be calcified guinea worm, and he was reassured.

Discussion

Infection with *Dracunculus medinensis* is common in many parts of tropical Africa, the Middle East, and southern Asia (Lucas, 1971). It is well known that the adult worm presents on the surface of the body on the feet, ankles, lower limbs and, occasionally, on the backs of the water carriers. However, invasion of the genital area has been reported only in the

scrotum, where it forms an abscess or, in late cases, may become calcified, palpable alongside the epididymis, and is visible on radiographs (Willcox, 1964).

The excursion of the guinea worm into the inguinal gland producing an adenitis is not only an unusual presentation but is also likely to create diagnostic problems in tropical areas where inguinal adenitis may be produced by many conditions including sepsis in the feet, tuberculosis, lymphogranuloma venereum, chancroid, and syphilis. In these conditions, the bubo aspirates are frequently examined by staining with Gram, Ziehl Nielsen, Giemsa and other methods, and by cultural techniques. If a wet preparation of the pus is not examined microscopically, it is likely that the diagnosis of guinea worm inguinal adenopathy will be missed, particularly in the pre-eruptive stage. It is suggested that the microscopical examination of a wet preparation of bubo aspirate should form part of the routine examination of patients with inguinal adenopathy, particularly in tropical countries.

The presence of the worm in the gland may be explained by its ability to bore its way through connective tissues and it is conceivable that it could find its way through the lymphatics into the inguinal glands, where it stimulates an inflammatory reaction.

Another unusual feature of this case is that, while it has been reported that subacute sterile abscesses are produced by the premature death of the female *Dracunculus medinensis* with liberation of the embryos into the subcutaneous tissue (Manson-Bahr, 1966), in this case, a live protruding worm emerged from the bubo by spontaneous rupture of the skin without the characteristic vesiculation of the pre-eruptive stage, which usually helps in diagnosis.

The effectiveness of niridazole in the treatment of dracontiasis has been reported by Lucas (1971) and was confirmed in this case. Thiabendazole has also been reported to be effective at the total dose of 100 mg per kg body weight in divided doses during a 24-hour period (Lucas, 1971).

References

- Lucas, A. O. (1971). In *Management and Treatment of Tropical Diseases*. Edited by B. G. Macgrath and H. M. Giles. Blackwell: Oxford.
- Manson-Bahr, P. H. (1966). *Manson's Tropical Diseases*, 16th edition. Baillière, Tindall, & Cassell: London.
- Willcox, R. R. (1964). *Textbook of Venereal Diseases and Treponematoses*, 2nd edition. Heinemann: London.