

Syphilitic alopecia and Jarisch-Herxheimer reaction

S. S. PAREEK

From St James's Hospital, Birkenhead

Introduction

The Jarisch-Herxheimer reaction was first described by Jarisch (1895) and elaborated by Herxheimer in 1902 (Stokes *et al.*, 1944). The reaction was characterised by a transient aggravation of the local and general manifestations, and most of the features would have gone by the next day.

This report concerns a patient with syphilitic alopecia who showed a marked febrile reaction six hours after the first injection; alopecia also became diffuse and extensive but after treatment the hair grew again normally. To my knowledge this association has not been described before.

CASE REPORT

A 25-year-old married man who presented on 23 February 1977 had noted a progressive loss of scalp hair since January. Six weeks earlier he had had marital sexual intercourse and two months before that his wife had been treated for syphilis. In January he had had a slight rash comprising small macules and papules which had been non-irritating and was mainly present on the buttocks; this had cleared after two weeks. At the same time he became aware of warty lesions at the anus. There was no history of physical trauma or any fungal infection. He had not been taking drugs.

On examination the patient looked ill and his temperature was 100°F (37.8°C). There was no skin eruption. There was generalised lymphadenopathy with discrete, non-tender, firm, and mobile lymph nodes. There were moist hypertrophic papular lesions at the anus. There was widespread thinning of scalp hair, eyebrows, and pubic area. The scalp showed patchy alopecia which presented a characteristically 'moth eaten' appearance (Fig. 1).

The patient's full blood count was normal and the erythrocyte sedimentation rate was 10 mm in the first hour (Westergren). Thyroid function tests, blood sugar, lupus erythematosus cells, and serum

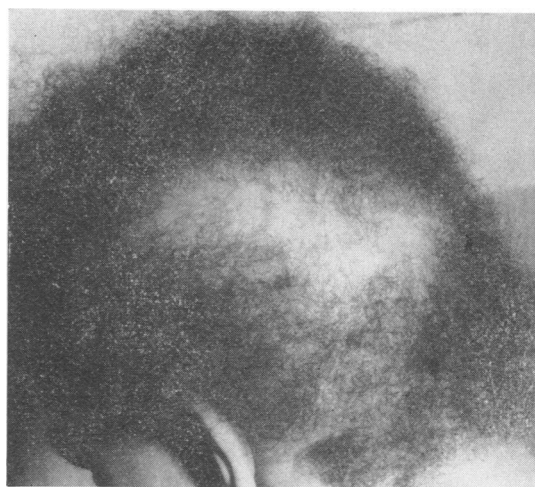

Fig. 1 Syphilitic alopecia showing 'moth eaten' appearance.

proteins were normal. Immunoglobulin assay, urine analysis, chest x-ray, and electrocardiograms were also normal. Darkground examination of serum from one of the anal condylomata lata showed *Treponema pallidum* and the cardiolipin Wassermann reaction was positive at 1:80. Fluorescent treponemal antibody absorption (FTA-ABS) and treponemal haemagglutination (TPHA) tests also gave positive results. Histopathological examination of the scalp skin showed infiltration by lymphocytes and plasma cells around the blood vessels and hair follicles.

The patient was treated with 1.2 megaunits of procaine penicillin daily for 10 days. Six hours after the first injection the temperature rose to 103°F (39.4°C) and he complained of malaise, headache, flushing, and sore throat. There was a transient skin rash and marked loss of hair (Fig. 2). All the symptoms had disappeared by the next day. The condyloma lata resolved within a week of starting penicillin treatment. Two to three weeks later the lymphadenopathy had disappeared and the eyebrows and pubic hair started to grow again. Scalp hair had regrown 10 weeks from the onset of treatment (Fig. 3).

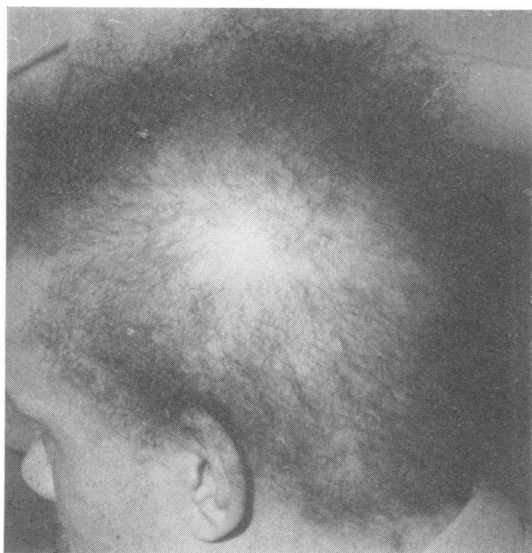

Fig. 2 Diffuse and extensive alopecia caused by Jarisch-Herxheimer reaction six hours after first injection of penicillin.

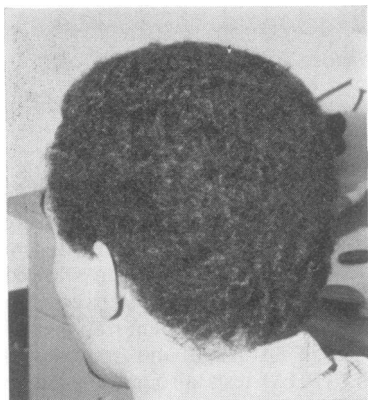


Fig. 3 Regrowth of hair after 10 weeks of treatment.

Discussion

In the absence of another explanation it is reasonable to assume that the alopecia was caused by syphilis although treponemes were not identified in the scalp skin. Diffuse and extensive hair loss after the first injection of penicillin suggested that this was part of the Jarisch-Herxheimer reaction. The mechanism of this reaction is not yet clearly understood but it is common in early syphilis and fatal reactions have been reported in late syphilis (Scott *et al.*, 1949) and in congenital syphilis (Ehregut, 1950; Stenger, 1950). Satisfactory progress of this patient suggest that the Jarisch-Herxheimer reaction has little effect on the prognosis of syphilitic alopecia even when this becomes dramatically severe during the reaction.

I am indebted to Dr F. Lanceley, consultant venereologist for his encouragement and guidance and his permission to report this case.

References

- Ehregut, W. (1950). Ein Beitrag zur Beurteilung und Verhütung von Spirochidenschäden. *Archiv für Kinderheilkunde*, **140**, 123-144.
- Jarisch, A. (1895). Therapeutic trial for syphilis. *Wiener Medizinische Wochenschrift*, **45**, 721-771.
- Scott, V., Maxwell, R. W., and Skinner, J. S. (1949). The Jarisch-Herxheimer phenomenon in late syphilis. *Journal of the American Medical Association*, **139**, 217-220.
- Stenger, K. (1950). Der Mechanismus des Keuchhustenan falles und die expiratorische apone Kindesarzt. *Monatsschrift für Kinderheilkunde*, **98**, 462-471.
- Stokes, J. H., Beerman, H., and Ingraham, N. R. (1944). *Modern Clinical Syphilology*, third edition, p. 131. Saunders: Philadelphia.