

## Rectal spirochaetosis

D W K COTTON,\* N KIRKHAM,\* AND D A HICKS†

From the \*Department of Pathology, Southampton General Hospital, Southampton, and the

†Department of Genitourinary Medicine, Royal Liverpool Hospital, Liverpool

**SUMMARY** We report four cases of rectal spirochaetosis, one in an active male homosexual. One of the heterosexual patients was referred to the genitourinary clinic by a general surgeon after spirochaetes had been found on histopathological examination of a rectal biopsy specimen. We doubt that most of our cases represent sexual transmission of spirochaetosis, or that the condition causes disease in most people. Rectal spirochaetosis possibly occurs only when the normal flora of the gut are disturbed for other reasons. Most of our patients became asymptomatic after non-specific treatment, although metronidazole appears to be specific.

### Introduction

Spirochaetosis of the intestinal tract in man is not uncommon although it is rarely diagnosed. Incidences of 10% in consecutive human rectal biopsy specimens<sup>1</sup> and 7·8% in surgically removed appendices<sup>2</sup> have been reported, while other authors have found an incidence of 1·9% and 2·1% respectively.<sup>3</sup> There is a similar disagreement regarding the importance of these infestations, some authors considering them to be regularly associated with symptoms<sup>1</sup> while others feel that such associations are the exception.<sup>3</sup> In Rhesus monkeys the prevalence of large bowel infestation was about 14% and was seldom associated with symptoms,<sup>3</sup> while in swine colonic lesions have been attributed to the presence of spirochaetes.<sup>4</sup> The significance of such infestations in a variety of species was reviewed by Harris and Kinyon, who concluded that only in the case of swine dysentery had spirochaetosis been proved to cause disease.<sup>5</sup>

Case reports associate intestinal spirochaetosis in man with diarrhoea,<sup>1</sup> bleeding,<sup>6</sup> purulent discharge,<sup>7</sup> and a variety of sexually transmitted diseases in homosexual men.<sup>8</sup> Whatever disorders are caused by intestinal spirochaetosis in man, it is becoming relatively well known in pathological and gastroenterological publications and is consequently being reported more often by pathologists as an incidental finding. One of the cases we report was recognised in this way and was inappropriately referred to a genitourinary clinic by surgeons.

We report four new cases of rectal spirochaetosis which presented in a variety of ways, and review the

significance of this condition and the disorders it causes.

### Case reports

#### CASE 1

A 32 year old practising male homosexual was admitted as a medical emergency in September 1982. He gave a three week history of intermittent diarrhoea with some mucus, night sweats, headaches, and a rash which had begun that day. He had returned from Italy two months previously where he had had sexual contact with two men. He had not had more recent sexual contact and did not have a regular sexual partner. He had been treated for gonorrhoea in February 1982. Examination showed an inflamed anal margin. A diffuse pink-brown papular skin rash extended to the soles of his feet. Sigmoidoscopic examination showed blood and yellow stools, but no gross mucosal lesion except for point of contact bleeding at 8 cm. Histological examination of a biopsy specimen taken from this level showed no inflammation, but there was a marked haematophylic line over the mucosa, and spirochaetosis was diagnosed. This finding was confirmed by electron microscopy. The Venereal Disease Research Laboratory (VDRL) test, which had given a negative result, was positive at a titre of 1/16 when repeated. He was treated with 1·2 MU procaine penicillin intramuscularly plus 30 mg prednisolone daily. He made an uneventful recovery and was well when seen at follow up in February 1983.

#### CASE 2

A 29 year old man was seen in the surgical clinic with a twelve week history of profuse diarrhoea, perianal pain, and weight loss associated with colicky

Address for reprints: Dr D W K Cotton, Department of Pathology, Southampton General Hospital, Southampton SO9 4XY

Accepted for publication 22 July 1983

abdominal pains. The attacks began towards the end of an 18 month prison sentence. On examination the patient was thin and pale but otherwise normal. Rectal examination was normal. Sigmoidoscopic examination to 22 cms showed pale mucosa, no bleeding, but some thin mucoid discharge. A biopsy specimen showed no evidence of active inflammatory bowel disease but intestinal spirochaetosis was found. A barium enema showed no abnormality. Because of the presence of spirochaetes he was referred to the genitourinary clinic. He denied having had homosexual intercourse, and heterosexual intercourse had only taken place before his prison sentence. Metronidazole 200 mg three times daily for three weeks was given without effect, but a second course led to resolution of the diarrhoea, and a further rectal biopsy specimen was free of spirochaetes.

#### CASE 3

A 71 year old man was investigated in August 1982 for intermittent diarrhoea (bowels open eight times a day) and lower abdominal pain over the previous six weeks. A similar episode two years previously had been diagnosed as diverticulitis. On examination a large mass in the left hypochondrium was thought to be splenic. Inguinal and axillary lymph nodes were palpable. Rectal examination was normal. Sigmoidoscopic examination showed a small polyp at the rectosigmoid junction, and red, granular, non-

friable mucosa. A rectal biopsy specimen showed large intestinal mucosa with normal architecture and mild active inflammation of the lamina propria. A haematoxyphilic haze on the surface of the epithelium suggested spirochaetosis. Barium enema showed diverticular disease, and haematological examination confirmed chronic lymphatic leukaemia. The patient's bowel symptoms settled after the addition of bran to his diet.

#### CASE 4

A 61 year old man was admitted to the medical wards in March 1983 complaining of colicky pain in the left iliac fossa. The pain came in bouts lasting a few days and was often relieved by defaecation. He had noticed a recent change in bowel habit from once a day to three times a day with occasional attacks of nocturnal diarrhoea. The stools contained mucus and some bright red blood over the surface. He had no other symptoms at the time although he had undergone haemorrhoidectomy in 1970. Routine haematological and biochemical tests gave normal results. Sigmoidoscopic examination to 15 cm was normal. A biopsy specimen taken from the rectum showed spirochaetosis on examination by light microscopy. This diagnosis was confirmed on examining the biopsy specimen by transmission electron microscopy. He was given a course of metronidazole 400 mg three times daily for one week, at the end of which his symptoms had resolved, and

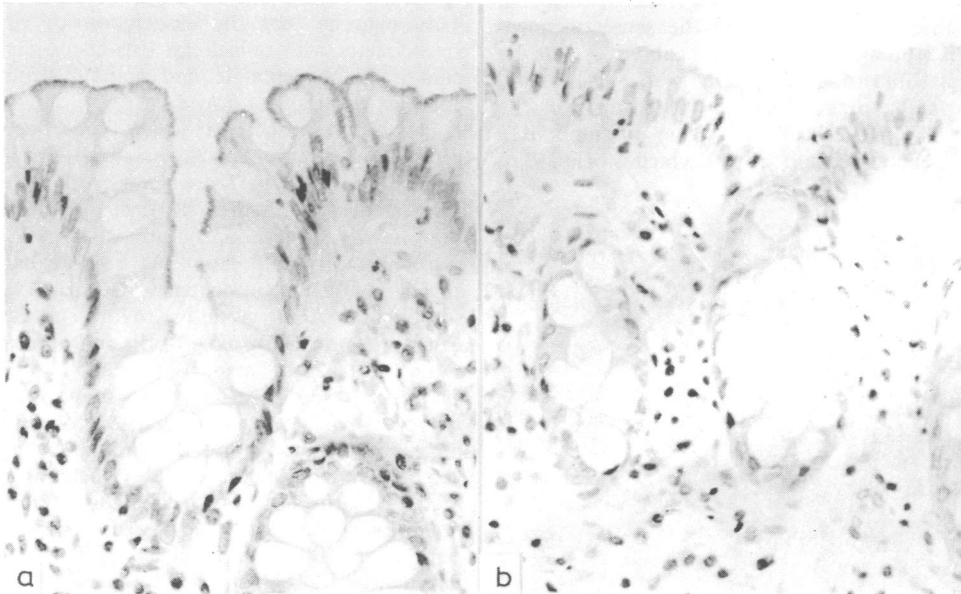


FIG 1 Case 4: a) Biopsy showing spirochaetosis of rectal mucosa. A pronounced haematoxyphilic band coats the mucosal surface. b) Same patient after treatment with metronidazole and resolution of symptoms. (Haematoxylin and eosin  $\times 300$  magnification.)

repeated biopsy examination showed no spirochaetosis. This was again confirmed on examination by transmission electron microscopy.

#### HISTOLOGICAL EXAMINATION AND ELECTRON MICROSCOPY

The characteristic appearance of spirochaetosis is a blue (haematoxyphilic) line at the brush border of the mucosal surface in sections stained with haematoxylin and eosin (Fig 1). This can be confirmed using a spirochaete silver stain (Dieterle). We have also used an antitreponemal antiserum raised in rabbits against *Treponema pallidum* in an immunoperoxidase system to stain intestinal spirochaetes using the method of Sternberger *et al.*<sup>9</sup> Examination of rectal biopsy specimens by scanning electron microscopy showed particularly well the large numbers of spirochaetes coating the surface (fig 2). Examination by transmission electron microscopy showed the attachment of spirochaetes to the epithelial cell surface between the microvilli (fig 3).

#### Discussion

Published reports seem to cover two conditions by the term "intestinal spirochaetosis"; one refers to spirochaetes recovered from faeces and the other, which we used, refers to spirochaetes attached to mucosal surfaces. Early observers reported spirochaetes in the faeces of cholera patients.<sup>10</sup> Leach *et al* showed that spirochaetosis, in the sense of spirochaetes in the faeces, could be caused in rats by inducing diarrhoea to flush out the normal (commensal) spirochaete population into the faeces.<sup>11</sup> The earliest sign of swine dysentery is a mucosally associated spirochaete which is believed to

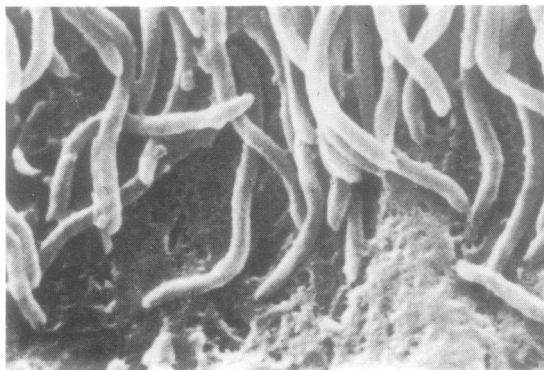


FIG 2 Large numbers of spirochaetes coat the mucosal surface and obscure the underlying microvilli. (Scanning electron microscope  $\times 17\,750$  magnification.)

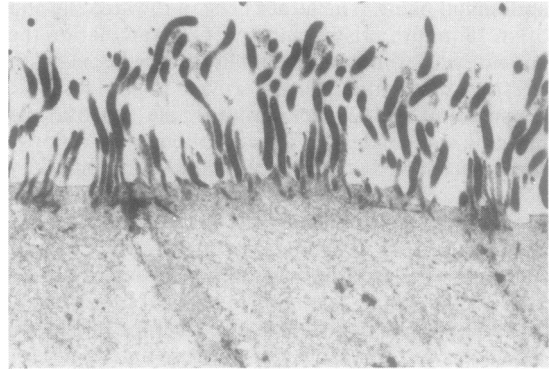


FIG 3 *Spirochaetes* are attached to the epithelial cell surface between the microvilli. (Transmission electron microscope  $\times 8000$  magnification.)

cause the dysentery, during which it may be found in large numbers in the faeces.<sup>4</sup> Examination of these spirochaetes by scanning electron microscopy shows a picture similar to that seen in man<sup>2,3</sup> and the Rhesus monkey.<sup>3,12</sup>

Spirochaetes may be found attached to a variety of cell surfaces, including those of unicellular organisms.<sup>13</sup> The nature of their highly specific attachment mechanisms has been studied extensively.<sup>14</sup> The ubiquity of these associations has led to the inclusion of spirochaetes in the serial endosymbiotic theory of the origin of eukaryote cells. This suggests that the association of primordial spirochaetes with unicellular organisms gave rise to cilia and the centriole and spindle structures of complex cells as they now exist.<sup>15</sup>

It is by no means clear which type of spirochaete infests the human bowel. In swine dysentery the organism seems to be *Treponema hyodysenteriae* or a similar species.<sup>4</sup> In man no firm identification has been achieved, although Kaplan claimed that the spirochaete isolated from his homosexual patient suffering from a purulent discharge was non-treponemal.<sup>7</sup> Harris and Kinyon suggested that organisms possessing axial fibrils and occurring in the intestinal tract of man be termed, by definition, *Treponema* species.<sup>5</sup> They also suggested that the name "*Borrelia*" should be restricted to spirochaetes borne in the blood and transmitted by arthropod vectors. Our finding that rectal spirochaetes from man reacted with serum raised against *Treponema pallidum* would support this. A further identification point is that all the spirochaetes we observed showed left handed (anticlockwise) spirality. Although the direction of the spiral does not distinguish between *Treponema* spp and *Borrelia* spp, as a whole it is thought to be constant for any one species.<sup>16</sup>

As to the question of whether or not these organisms cause disease, their behaviour may depend on the other organisms in their environment. The oral condition of Vincent's angina is caused by symbiotic relationships between spirochaetes and other organisms. The binding of spirochaetes to mammalian cell membranes, however, is probably an essential first step in any pathogenic process.<sup>17</sup>

Finally, the route of infection remains obscure. Although the incidence of spirochaetosis is greater in homosexual men,<sup>8</sup> anal intercourse is an unlikely explanation of infection in all our patients. Nevertheless, these organisms may frequently be spread by this form of intercourse, and spirochaetosis should be borne in mind when diagnosing a homosexual patient with proctitis, a purulent rectal discharge, unexplained diarrhoea, or rectal bleeding. The cases which have been studied and followed up seem to respond well to metronidazole. Although the cause is obscure, therefore, the treatment is effective.

We thank the medical laboratory scientific staff of the histopathology, electron microscopy, and experimental pathology laboratories of Southampton General Hospital for their expert technical assistance.

#### References

1. Harland WA, Lee FD. Intestinal spirochaetosis. *Br Med J* 1967;iii: 718-9.
2. Lee FD, Krazewski A, Gordon J, Howie JGR, McSeveney D, Harland WA. Intestinal spirochaetosis. *Gut* 1971;12: 126-33.
3. Takeuchi A, Jarvis HR, Nakazawa H, Robinson DM. Spiral shaped organisms on the surface colonic epithelium of the monkey and man. *Am J Clin Nutr* 1974;27: 1287-96.
4. Kennedy GA, Strafuss AC. Scanning electron microscopy of the lesions of swine dysentery. *Am J Vet Res* 1976;37: 395-401.
5. Harris DL, Kinyon JM. Significance of anaerobic spirochetes in the intestines of animals. *Am J Clin Nutr* 1974;27: 1297-304.
6. Douglas JG, Cruciolli V. Spirochaetosis: a remediable cause of diarrhoea and rectal bleeding? *Br Med J* 1981;283: 1362.
7. Kaplan LR, Takeuchi A. Purulent rectal discharge associated with a nontreponemal spirochete. *JAMA* 1979;241: 52-3.
8. McMillan A, Lee FD. Sigmoidoscopic and microscopic appearance of the rectal mucosa in homosexual men. *Gut* 1981;22: 1035-41.
9. Sternberger LA, Hardy PH, Cuculis JJ, Meyer HG. The unlabelled antibody enzyme method of immunochemistry. *J Histochem Cytochem* 1970;18: 315-33.
10. Escherich T. Beitrage zur Kenntnis der Darmbakterien. *Muenchener Medizinische Wochenschrift* 1886;33: 815-7.
11. Leach WD, Lee A, Stubbs RP. Localisation of bacteria in the gastrointestinal tract: a possible explanation of intestinal spirochaetosis. *Infect Immun* 1973;7: 961-72.
12. Takeuchi A, Zeller JA. Scanning electron microscopic observations on the surface of the normal and spirochaete-infested colonic mucosa of the Rhesus monkey. *J Ultrastruct Res* 1972;40: 313-24.
13. Bloodgood RA, Miller KR, Fitzharris TP, McIntosh JR. Ultrastructure of *Pyronympha* and its associated microorganisms. *J Morphol* 1974;143: 77-106.
14. Neutra MR. Prokaryotic-eukaryotic cell junctions: attachment of spirochetes and flagellated bacteria to primate large intestinal cells. *J Ultrastruct Res* 1980;70: 186-203.
15. Margulis L, Chase D, To LP. Possible evolutionary significance of spirochaetes. *Proc Soc Lond [Biol]* 1979;204: 189-98.
16. Stepan DE, Johnson RC. Helical conformation of *Treponema pallidum* (Nichols strain), *Treponema paraluis cuniculi*, *Treponema denticola*, *Borrelia turicatae*, and unidentified oral spirochaetes. *Infect Immun* 1981;32: 937-40.
17. Wong GHW, Steiner B, Faine S, Graves S. Factors affecting the attachment of *Treponema pallidum* to mammalian cells in vitro. *Br J Vener Dis* 1981;59: 21-9.