

Cryotherapy in the management of cervical ectopy

K C MOHANTY,* R J RAND,† AND B BERRY‡

From the Departments of *Genitourinary Medicine and †Gynaecology, St Luke's Hospital, Bradford, and ‡Airedale General Hospital, Steeton, West Yorkshire

SUMMARY Sixty five patients with benign ectopy of the uterine cervix were treated by cryosurgery in the departments of genitourinary medicine at St Luke's Hospital, Bradford, and the Airedale General Hospital, West Yorkshire, without analgesia or anaesthesia. A symptomatic cure rate of 98% was achieved. There were no serious complications. This treatment is considered to be appropriate in genitourinary clinics in the United Kingdom as these have routine screening procedures for various genital infections.

Introduction

Large numbers of patients with vaginal discharge are now attending genitourinary departments rather than going to their general practitioners or gynaecologists. Many of such patients have, and all those included in this study had, associated cervical ectropion—that is, extension of endocervical columnar epithelium on to the ectocervix. Cryosurgery is considered to be the most useful treatment of this condition.¹ (Cervical erosion, which is defined as a loss of epithelium covering the surface of the cervix, is a different disease and should not be treated with cryosurgery.²)

Patients, materials, and methods

The 65 patients studied were aged between 17 and 31. All had columnar epithelium extending on to the ectocervix for at least 0.5 cm from the external cervical os (figure). This was generally associated with a vaginal discharge. Many also had intermenstrual bleeding, postcoital bleeding, dyspareunia, or vaginal pain associated with superficial cervicitis. The patients consisted of two groups: 50 had cervical ectopy but no genital infection, and 15 had cervical ectopy associated with a vaginal discharge that persisted after the appropriate antibiotic treatment of genital infection.

All 65 patients were seen in the clinics for women of the departments of genitourinary medicine at St Luke's Hospital, Bradford, or the Airedale General Hospital, Steeton. They underwent routine vaginal

examinations and screening tests for the presence of *Neisseria gonorrhoeae*, *Chlamydia trachomatis*, *Trichomonas vaginalis*, *Candida albicans*, *Gardnerella vaginalis*, and anaerobes. Serological tests for syphilis were performed. Cervical smears, none of which showed atypical cells, were taken from all patients. Patients with genital warts were excluded from the study. The cervix was examined in bright light with the naked eye after being mopped with cotton swabs. Appropriate cervical probes were used according to the size of the ectropion, and nitrous oxide gas was used as a refrigerant (cryosurgical apparatus was supplied by Keymed, England). A low temperature (–60°C to –70°C) was achieved with the Joule-Thomson effect in the cervical probes. Freezing was undertaken for 90 seconds on the first occasion and for 180 seconds on the second occasion, one week later. The patients were followed up at six, 12, and (in 20 (30.7%) cases) 24 weeks.

Results

Of the 50 patients with cervical ectopy but no detectable genital infection, 49 (98%) responded to cryosurgery. Both the vaginal discharge and ectopy had disappeared after six weeks in 46 (92%) and after 12 weeks in 49 (98%). No serious side effects were noticed, in particular no appreciable haemorrhage occurred, although five patients in this group had mild abdominal pain and dizziness that lasted for 10 minutes after treatment.

All 15 patients who had persistent vaginal discharge associated with cervical ectropion after a specific genital infection had been cured responded to cryosurgery. None had any appreciable side effects.

Address for reprints: Dr K C Mohanty, Consultant in Genitourinary Medicine, St Luke's Hospital, Bradford, West Yorkshire BD5 0NA

Accepted for publication 14 January 1985

Discussion

Colposcopic and histological observations have shown that the healing process of cervical ectopy after cryotherapy is achieved completely by metaplasia of the mucous membrane to squamous epithelium.¹ Flattening of the exposed columnar epithelium can be seen on the second day, and is followed by hyperplasia of the epithelial cells and finally their metaplasia to form squamous epithelium, which occurs in two to 10 weeks.¹ We therefore examined all our patients 12 weeks after cryosurgery.

When we started this study we used a single three minute freeze, which resulted in an appreciable failure rate and side effects, such as severe abdominal cramps, flushing of the face, and dizziness. Many workers have used a cycle of freezing and defrosting—that is, a three minute freeze followed by a 10 minute defrost period and a second three minute freeze, which resulted in more effective cellular destruction.³ This method of cryosurgery, however, also produced side effects in our patients. We there-

TABLE I *Effect of cryosurgery on 50 patients with cervical ectopy but no detectable genital infections*

Initial symptoms	No of patients (n = 50)	No with serious side effects	No cured after:	
			6 weeks	12 weeks
Vaginal discharge	45	0	40	44
Dyspareunia	16	0	16	16
Postcoital bleeding	8	0	8	8
Intermenstrual bleeding (spotting on underwear)	11	0	11	11
Pain in vagina	1	0	1	1

TABLE II *Effect of cryosurgery on 15 patients with cervical ectopy that caused persistent vaginal discharge after specific genital infections had been cured*

Previous infection with:	No of patients (n = 15)	No cured after 6 weeks
<i>Neisseria gonorrhoeae</i>	4	4
<i>Chlamydia trachomatis</i>	5	5
<i>N gonorrhoeae</i> and <i>C trachomatis</i>	3	3
<i>Trichomonas vaginalis</i>	1	1
<i>Candida albicans</i>	1	1
<i>Gardnerella vaginalis</i>	1	1

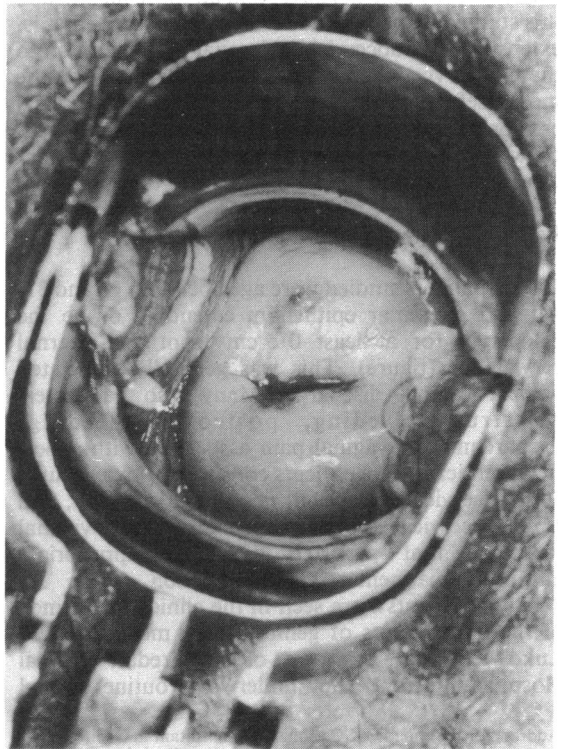
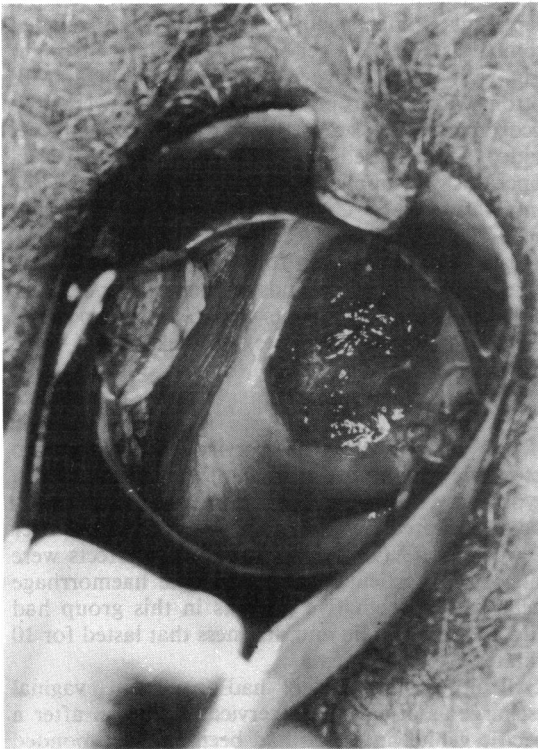

FIGURE *Cervical ectopy (left) cured six weeks after cryosurgery (right).*

fore changed the procedure to freezing for 90 seconds at the first visit, irrespective of the size of the area of ectropion, and for 180 to 300 seconds according to the size of the ectropion at the second visit a week later. This was well tolerated by almost all patients. Patients were warned to expect a brownish vaginal discharge with occasional bleeding for about two weeks after cryotherapy.

A cure was defined by the subjective improvement of symptoms and the replacement of the exposed mucous membrane by healthy squamous epithelium. The cure rate for patients with no detectable genital infections was 98% (table I), whereas 100% of patients who had been treated for a specific infection were cured (table II). This shows that cervical ectopy responds very well if patients are screened and treated for any possible genital infections before cryosurgery. Some reports show a higher failure rate (30%) because patients have not been screened for genital infections before cryosurgery.² Other studies describe a higher cure rate (95%) when patients are screened before cryotherapy.⁴

We think that cryosurgery is particularly suited to genitourinary clinics in the United Kingdom, where

extensive screening for all kinds of genital infections and cervical cytology are undertaken routinely. It has the advantage of being safe, it is easy to operate as an outpatient procedure without analgesia or anaesthesia, it is well tolerated by patients, and has a cure rate of almost 100%.

We thank Mrs V Maude, Sister A Stodart, Staff Nurse A M C Sharp, Nurse C Foers, and Rachel Atkinson for their help and Ms Pat Lodge for typing the manuscript.

References

1. Kashimura M. Reparative process of benign erosion of the uterine cervix following cryosurgery. *Gynecol Oncol* 1980;9: 334-50.
2. Ruiz-Moreno JA. Cervical erosion. *Gynecol Oncol* 1981;12: 268.
3. Kaufman RH, Strama T, Norton PK, Conner JS. Cryosurgical treatment of cervical intraepithelial neoplasia. *Obstet Gynecol* 1973;42:881-6.
4. Young C, Malvern J, Chamberlain G. Out-patients cervical cryosurgery. *Journal of Obstetrics and Gynaecology of the British Commonwealth* 1972;79:753-5.