



OPEN ACCESS

Mpox proctitis as a likely predisposing factor for chlamydial perihepatitis in a male patient

Shir Azrielant ¹, Amichai Sheffy, ^{2,3} Fahim Kanani, ⁴ Israel Nissan, ⁵ Amos Adler, ^{6,3} Michal Dekel ^{7,3}

¹Division of Dermatology, Tel Aviv Sourasky Medical Center, Tel Aviv, Israel

²Emergency Department, Tel Aviv Sourasky Medical Center, Tel Aviv, Israel

³Sackler Faculty of Medicine, Tel Aviv University, Tel Aviv, Israel

⁴General Surgery Division, Tel Aviv Sourasky Medical Center, Tel Aviv, Israel

⁵Public Health Services, Ministry of Health, National Public Health Laboratory, Tel Aviv, Israel

⁶Clinical Microbiology Laboratory, Tel Aviv Sourasky Medical Center, Tel Aviv, Israel

⁷Infectious Diseases Unit, Tel Aviv Sourasky Medical Center, Tel Aviv, Israel

Correspondence to

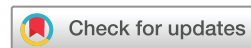Dr Shir Azrielant, Division of Dermatology, Tel Aviv Sourasky Medical Center, Tel Aviv, Israel; shirazrielant@gmail.com

Received 13 January 2023

Accepted 10 February 2023

Published Online First

7 March 2023



© Author(s) (or their employer(s)) 2023. Re-use permitted under CC BY-NC. No commercial re-use. See rights and permissions. Published by BMJ.

To cite: Azrielant S, Sheffy A, Kanani F, et al. *Sex Transm Infect* 2023;**99**:287–288.

ABSTRACT

Perihepatitis (Fitz-Hugh-Curtis syndrome) is a rare complication of sexually transmitted infections, mostly seen in women. Only 12 male cases have been reported to date, of which *Chlamydia trachomatis* was confirmed in 2. We report a case of chlamydial perihepatitis in a male patient, occurring 1 month after Mpox and associated with the unusual LGV ST23 strain. Our case suggests that rectal Mpox lesions may facilitate chlamydial dissemination.

BACKGROUND

Mpox, once a rare zoonotic viral disease, is now an emerging sexually transmitted infection (STI). The recent outbreak is characterised by human-to-human transmission and newly described complications.¹ Perihepatitis (Fitz-Hugh-Curtis syndrome) is a rare complication of pelvic inflammatory disease caused by STIs. It is rare in men, possibly because it requires an anatomical port of entry.²

PRESENTATION

A 37-year-old man presented to the emergency department (ED) with a 10-day history of high-grade fever, malaise and abdominal left upper-quadrant (LUQ) pain. He appeared septic. This was his third visit to the ED since symptoms began. On his first visit, a physical examination revealed slight LUQ tenderness; blood tests showed only slightly elevated C reactive protein (CRP, 31 mg/L). On his second visit, abdominal CT showed minimal intraperitoneal fluid without the evidence of colitis. Alanine aminotransferase (ALT) was mildly elevated (83 U/L), and the CRP was 158 mg/L. On both visits, he was discharged without a specific diagnosis or treatment.

A month prior to the first ED presentation, the patient had experienced fever, severe abdominal and rectal pain and lesions on his buttocks, genitalia and neck, and was diagnosed with Mpox. The diagnosis was confirmed by a positive PCR. Complete STI screening panels were negative, including PCR for *Chlamydia trachomatis*, *Neisseria gonorrhoeae* and *Mycoplasma genitalium* from the pharynx, rectum and urethra, as well as HIV and venereal disease research laboratory (VDRL) serologies. Treponema pallidum hemagglutination assay (TPHA) was positive due to a previous infection. His social history included sexual activity with multiple male partners without barrier protection, both before his Mpox infection and soon after his recovery from it. He

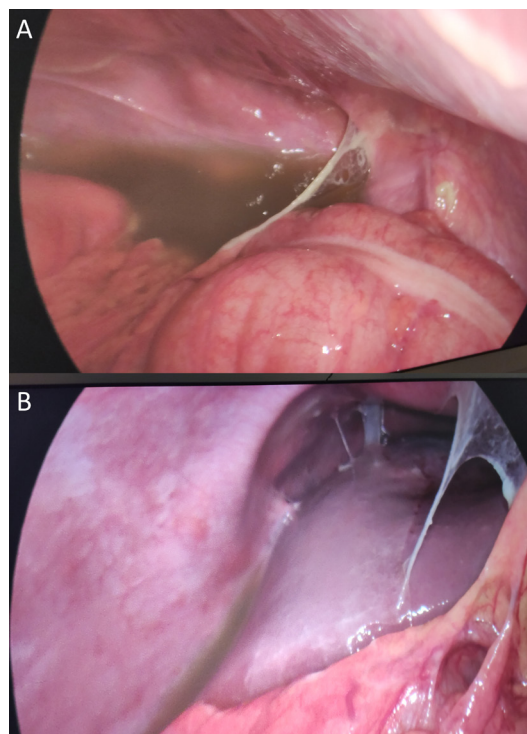


Figure 1 A laparoscopic view of cloudy peritoneal fluid and violin string-like adhesions on the right colic flexure (A) and around the liver (B).

had been taking emtricitabine/tenofovir for HIV pre-exposure prophylaxis for 6 years.

INVESTIGATIONS

Clinical examination revealed signs of peritoneal irritation. Laboratory tests showed haemoglobin 10.8 g/dL, mildly elevated liver function tests (ALT of 75 U/L, aspartate aminotransferase of 81 U/L and gamma-glutamyl transferase of 81 U/L) and a CRP of 402 mg/L. A repeat CT showed large fluid collections in the perihepatic and perisplenic spaces and thickening of the peritoneal lining, without signs of colitis. An urgent diagnostic laparoscopy revealed cloudy peritoneal fluid and diffuse violin string-like adhesions (figure 1A,B). PCR from peritoneal fluid was positive for *C. trachomatis* and negative for *N. gonorrhoeae* and *M. genitalium*. Bacterial and fungal cultures were negative. Sequencing was performed at the National Reference Laboratory. Lymphogranuloma venereum (LGV) was identified by the Allplex Genital Ulcer Assay. The sample was further analysed by *in-house* Multi Locus Sequence Typing.³ The strain was identified as LGV ST23.

Repeat STI and Mpox virus tests from pharynx, rectum and genitalia were negative. A careful rectal examination and anoscopy were negative for colitis and for other possible sites of perforation. Based on the findings, a diagnosis of chlamydial perihepatitis was made.

TREATMENT

The patient was hospitalised and monitored for 12 days and made a full recovery with doxycycline 100 mg orally two times daily for a total of 21 days.

DISCUSSION

Perihepatitis was believed to affect only women. However, 12 cases in men have been reported, of which *C. trachomatis* was confirmed in 2.^{2 4–10} The exact pathogenesis is not fully understood. In women, suggested mechanisms include ascending infection from the reproductive tract, extension through the lymphatic system and haematogenous spread. In men, the pathogenesis is more elusive.

Our patient had perihepatitis due to LGV ST23, a strain that had not been identified in Israel before. Although LGV may cause inflammatory bowel disease-like colitis and lymphadenitis, it was rarely described as a cause of perihepatitis.¹¹ Our case implies a port of entry. We propose that Mpox lesions in the rectum and the descending colon may have facilitated peritoneal dissemination of the LGV infection through the intestinal wall. We postulate that the patient's abdominal complaints while suffering from Mpox were signs of colorectal involvement. Our hypothesis is supported by the initial LUQ pain. Although no lesions were seen on rectal examination and anoscopy, the lesions might have healed by the time of the examination, 40 days after Mpox diagnosis. The negative STI screening panel at the time of the Mpox infection makes concomitant infection with Mpox and LGV unlikely and suggests instead that LGV was acquired subsequently. This is also consistent with the patient's sexual history. One other possibility is that the unusual LGV ST23 strain may show enhanced invasiveness that facilitated its peritoneal dissemination. In summary, this is the first report to propose Mpox as a potential facilitating factor for chlamydial perihepatitis in MSM, a new potential complication of Mpox. Our case is also unique in its causative pathogen, LGV ST23.

Learning points

- ⇒ Chlamydial perihepatitis may represent a new complication of Mpox in men, with colorectal lesions serving as a facilitating factor for dissemination.
- ⇒ Lymphogranuloma venereum ST23 is now circulating in Israel.

Handling editor Anna Maria Geretti

Acknowledgements The authors acknowledge Professor Eli Sprecher, Professor David Zeltser and Professor Ronen Ben-Ami for the assistance in case's publication. Dr Ari Safir provided patient care. Shlomo Pilo and Samuel Ezekiel provided assistance in LGV analysis.

Contributors SA: conceptualisation, data collection, planning and writing. AS: conceptualisation, data collection and patient management. FK: provided and cared for study patient. IN: writing, sequencing and analysing LGV strain. AA: critical review of the article. MD: conceptualisation, patient management, writing and guarantor.

Funding The authors have not declared a specific grant for this research from any funding agency in the public, commercial or not-for-profit sectors.

Competing interests None declared.

Patient consent for publication Obtained.

Provenance and peer review Not commissioned; internally peer reviewed.

Supplemental material This content has been supplied by the author(s). It has not been vetted by BMJ Publishing Group Limited (BMJ) and may not have been peer-reviewed. Any opinions or recommendations discussed are solely those of the author(s) and are not endorsed by BMJ. BMJ disclaims all liability and responsibility arising from any reliance placed on the content. Where the content includes any translated material, BMJ does not warrant the accuracy and reliability of the translations (including but not limited to local regulations, clinical guidelines, terminology, drug names and drug dosages), and is not responsible for any error and/or omissions arising from translation and adaptation or otherwise.

Open access This is an open access article distributed in accordance with the Creative Commons Attribution Non Commercial (CC BY-NC 4.0) license, which permits others to distribute, remix, adapt, build upon this work non-commercially, and license their derivative works on different terms, provided the original work is properly cited, appropriate credit is given, any changes made indicated, and the use is non-commercial. See: <http://creativecommons.org/licenses/by-nc/4.0/>.

ORCID iD

Shir Azrielant <http://orcid.org/0000-0002-1094-7113>

REFERENCES

- Patel A, Bilinska J, Tam JCH, *et al*. Clinical features and novel presentations of human monkeypox in a central London centre during the 2022 outbreak: descriptive case series. *BMJ* 2022;378:e072410.
- Takata K, Fukuda H, Umeda K, *et al*. Fitz-hugh-curtis syndrome in a man positive for Chlamydia trachomatis. *Clin J Gastroenterol* 2018;11:338–42.
- Pilo S, Zizelski Valenci G, Rubinstein M, *et al*. High-resolution multilocus sequence typing for chlamydia trachomatis: improved results for clinical samples with low amounts of C. trachomatis DNA. *BMC Microbiol* 2021;21:28.
- Kimball MW, Knee S. Gonococcal perihepatitis in a male. *N Engl J Med* 1970;282:1082–4.
- Winkler WP, Kotler DP, Saleh J. Fitz-Hugh and Curtis syndrome in a homosexual man with impaired cell mediated immunity. *Gastrointest Endosc* 1985;31:28–30.
- Davidson AC, Hawkins DA. Pleuritic pain: fitz Hugh Curtis syndrome in a man. *Br Med J (Clin Res Ed)* 1982;284:808.
- Fung GL, Silpa M. Fitz-Hugh and Curtis syndrome in a man. *JAMA* 1981;245:128.
- Francis TI, Osoba AO. Gonococcal hepatitis (Fitz-Hugh Curtis syndrome) in a male patient. *Br J Vener Dis* 1972;48:187–8.
- Nardini P, Compri M, Marangoni A, *et al*. Acute fitz-hugh-curtis syndrome in a man due to gonococcal infection. *J Emerg Med* 2015;48:e59–62.
- Lisičar I, Begovac J, Zekan S. A rare case of fitz-hugh-curtis syndrome caused by Chlamydia trachomatis in an HIV-positive male patient. *SAGE Open Med Case Rep* 2019;7:2050313X18823592.
- Di Altobrando A, Tartari F, Filippini A, *et al*. Lymphogranuloma venereum proctitis mimicking inflammatory bowel diseases in 11 patients: a 4-year single-center experience. *Crohn's & Colitis* 2019;1.

Supplementary – Hebrew abstract

תסמונת פיץ-יו-קרטיס היא סיבוך נדיר של מחלות המועברות במגע מיני, אשר מתרחשת לרוב בנשים. עד כה, דווח בספרות על 12 מקרים בלבד של גברים עם סיבוך זה, כאשר רק בשניים מהם זוהה הגורם המחולל ככלמידיה טרכומטיס. כאן, אנו מדווחים על מקרה של תסמונת פיץ-יו-קרטיס בגבר, עם זיהוי של המחולל כלמידיה טרכומטיס מהזן הנדיר LGV ST23, כחודש לאחר זיהום ב-Mpox. מקרה זה מעלה את האפשרות כי נגעי Mpox רקטלים עשויים להוות גורם המאפשר התפשטות תוך בטנית של כלמידיה.