



OPEN ACCESS

ORIGINAL ARTICLE

Tinea genitalis: a new entity of sexually transmitted infection? Case series and review of the literature

Isabelle Luchsinger,¹ Philipp Peter Bosshard,² Romano Silvio Kasper,² Dominic Reinhardt,¹ Stephan Lautenschlager¹

¹Outpatient Clinic of Dermatology, Triemli Hospital, Zurich, Switzerland
²Department of Dermatology, University Hospital Zurich, Zurich, Switzerland

Correspondence to

Professor Dr Stephan Lautenschlager, Outpatient Clinic of Dermatology, Triemli Hospital, Herman Greulichstrasse 70, Zurich CH-8004, Switzerland; stephan.lautenschlager@triemli.zuerich.ch

Received 3 February 2015

Revised 29 March 2015

Accepted 31 March 2015

ABSTRACT

Objective Investigation on recent cases of tinea genitalis after travelling to South East Asia.

Methods Patients with tinea in the genital region, which emerged after sex in South East Asia, underwent further assessment including microscopy, cultures and DNA analyses.

Results The case series includes seven patients. In six patients, *Trichophyton interdigitale* (former *Trichophyton mentagrophytes*) was detected. Three patients suffered from a severe inflammatory reaction of the soft tissue and two of them needed hospitalisation due to severe pain. In four patients, cicatrising healing was noticed. Five patients were declared incapacitated for work.

Conclusions Sexual activity should be considered as a potentially important and previously underappreciated means of transmission of *T. interdigitale*. To avoid irreversible scarring alopecia, prompt initiation of antifungal treatment is essential and adequate isolation and identification of the pathogen is mandatory.

and DNA analysis. Written consent for publication of each patient was obtained.

Specimens were obtained using skin scrapings of the affected area. Direct microscopic examination was performed by means of a 5% sodium dodecyl sulfate solution containing Congo red. Cultures were prepared on a selective agar medium (Selektivagar für pathogene Pilze 139e-20p, heipha Dr Müller GmbH, Germany) containing cycloheximide and chloramphenicol for 4 weeks at 25°C. For strain analysis the isolates were sequenced; DNA was extracted by using the Nexttec Genomic DNA Kit (Nexttec, Germany). The internal transcribed spacer (ITS) region was amplified using primers ITS1 and ITS4.¹⁰ Sequences were generated with the ITS4 primer and compared with the publicly available database (<http://www.cbs.knaw.nl/dermatophytes/BioLoMICSID.aspx>) and signature polymorphism.¹¹

RESULTS

Our first patient was an 18-year-old Eurasian woman from Sweden with no previous dermatological disease. She had repeated protected sexual intercourses in Thailand with a male Caucasian tourist. Furthermore, she practiced regular wet shaving of her pubic hair. One week after the first sexual intercourse, she noted red scaly lesions in the genital area. As her sexual partner earlier had comparable symptoms, she applied his clotrimazole cream. However, in the following 2 weeks she noticed spreading of the lesions and, additionally, headache and malaise. On consultation 2 weeks after onset of symptoms, erythematous scaling plaques and follicular pustules on her labia majora and mons pubis (figure 1) were observed. Significant regional lymphadenopathy was absent. Standard laboratory examinations showed leucocytosis ($14 \times 10^9/L$) and an elevated C-reactive protein level (30.8 mg/L). Direct microscopic examination revealed hyphae, and *T. interdigitale* was detected by culture. At the first examination, systemic treatment with terbinafine 250 mg daily was initiated and on suspicion of bacterial superinfection oral amoxicillin/clavulanic acid was administered. Due to severe pain, she was admitted to the hospital ward for analgetic therapy. After 2 days, a strong inflammatory reaction was observed. The pubic area (figure 2) showed succulent ulcerated nodules with seropurulent discharge. Antifungal treatment was switched to itraconazol 100 mg three times daily and, in addition, 50 mg oral prednisone was administered. Due to massive pain, the patient was

INTRODUCTION

Tinea corporis, a superficial cutaneous dermatophyte infection of the trunk and extremities, occurs worldwide and is most common in tropical regions. *Trichophyton interdigitale* (former *Trichophyton mentagrophytes*) is the second most frequent pathogen worldwide.¹ Contamination takes place by human-to-human and animal-to-human contact or soil-to-human spread. Recently, we repeatedly examined patients presenting with widespread dermatophytoses with *T. interdigitale* in the genital area. Dermatophytoses of the genital region are relatively rare compared with those involving the groin.²⁻⁵ Current literature only covers several cases of concomitant tinea genitalis in patients suffering from tinea inguinalis,⁶ tinea unguium, tinea pedis or tinea manuum,^{7,8} where auto-inoculation is postulated. In one case, an animal source of infection was supposed.⁹ We report on seven patients with tinea genitalis with probable sexual transmission presenting in early 2014.

PATIENTS AND METHODS

Between March and July 2014, seven patients (two female patients and five male patients; age range 18–55 years) consulted our outpatient clinics because of tinea in the genital region emerging after sexual intercourse in South East Asia. Five of these patients were treated at Triemli Hospital and two patients at University Hospital Zurich. Further work-up included microscopic assessment, cultures

To cite: Luchsinger I, Bosshard PP, Kasper RS, et al. *Sex Transm Infect* Published Online First: [please include Day Month Year] doi:10.1136/sextrans-2015-052036

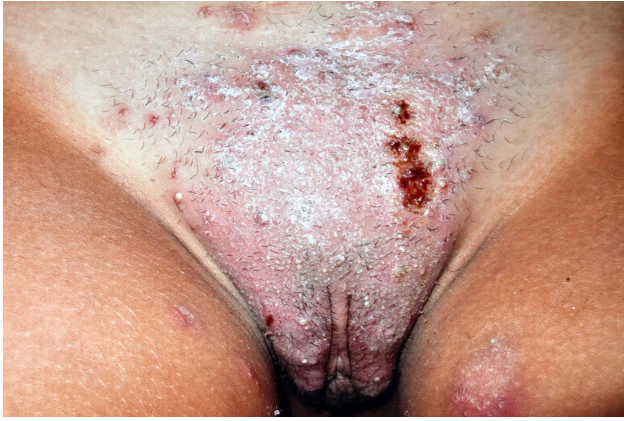

Figure 1 Erythematous scaling plaques and follicular pustules in an 18-year-old patient.

hospitalised for a total of 14 days. After 6 weeks of itraconazole and 3 weeks of prednisone, the lesions healed with marked scarring.

From March to July 2014, six additional patients with tinea in the genital area were treated in our clinics (five male patients and one female patient). These patients reported on having had sexual intercourse 1–2 weeks earlier in South East Asia. Four of the male patients had sexual contacts with local prostitutes. All of the patients declared the use of condoms and denied the use of lubrication.

Before consultation at our clinics, all patients had undergone topical treatments including corticosteroids, antibiotics or antifungals. The clinical presentation was comparable in all patients: sharply demarcated erythematous scaly plaques on mons pubis (figure 3), labia majora or proximal penile shaft, and in one patient additional involvement of the scrotum. Both female patients showed additional plaques on the gluteal region and one of them on the neck. One male patient had an additional lesion on the upper lips, and another one on the forearm. In four patients, yellow follicular pustules and in three patients, swollen inguinal lymph nodes were noticed. Five patients had a shaved pubic area. In all cases, the genital region was affected first, before spread to other regions was noted.

In all seven patients, direct examination revealed hyphae. Cultures were positive in six cases; the isolates were identified as *T. interdigitale*. The strains were subjected to sequence analysis for further investigation. When compared with the signature polymorphisms published by Heidemann *et al*,¹¹ three

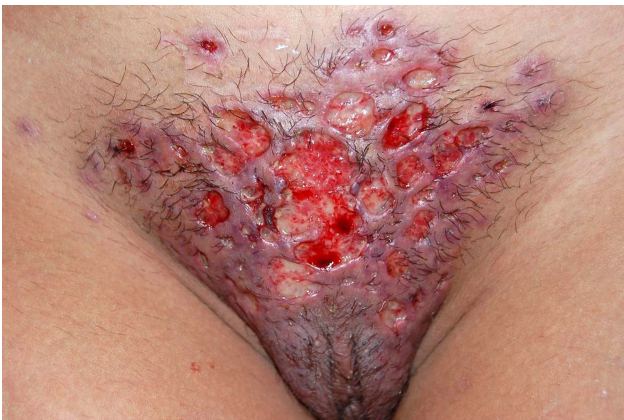

Figure 2 Pubic area with succulent ulcerated nodules with seropurulent discharge 2 days after beginning of antifungal treatment.

strains corresponded to *T. interdigitale* type III and three were similar to *T. interdigitale* type IV with some additional substitutions. It is very likely that they were originally of zoophilic origin. In three patients, bacterial culture was performed which remained negative. Examinations for other sexually transmitted infections were negative in all patients.

All patients required systemic antifungal treatment. Six patients were treated with terbinafine, and one patient with itraconazole. The duration of treatment was between 2 and 10 weeks (mean 5 weeks). The initial local treatment varied from ciclopirox cream (3 patients), clotrimazole cream (2 patients), terbinafine cream (1 patient) and fucidic acid cream (1 patient) combined with halometason/triclosan and betadine gauzes. Due to inflammation after starting antifungal treatment in three patients, systemic prednisone was administered for 6–21 days. Three patients received additional systemic antibiotics. As a consequence of severe pain, five patients required analgetic therapy. Two patients needed hospitalisation because of severe pain (3 and 14 days, respectively). A total of five patients were declared unfit for work (6–14 days). In four patients, cicatrisant healing was noticed.

DISCUSSION

We present seven cases with dermatophyte infection in the genital region after sexual intercourse in South East Asia 1–2 weeks earlier. To the best of our knowledge, just one case of sexual transmission in a Danish couple has been reported in the current literature.¹² In this case, an underlying *T. mentagrophytes* was found and severe inflammation was observed, as in our cases. In addition, it has been reported that genital dermatophytoses are more often seen in tropical countries, where the warm-humid climate leads to local humidity and skin maceration.^{13 14} This might be an explanation why the reported

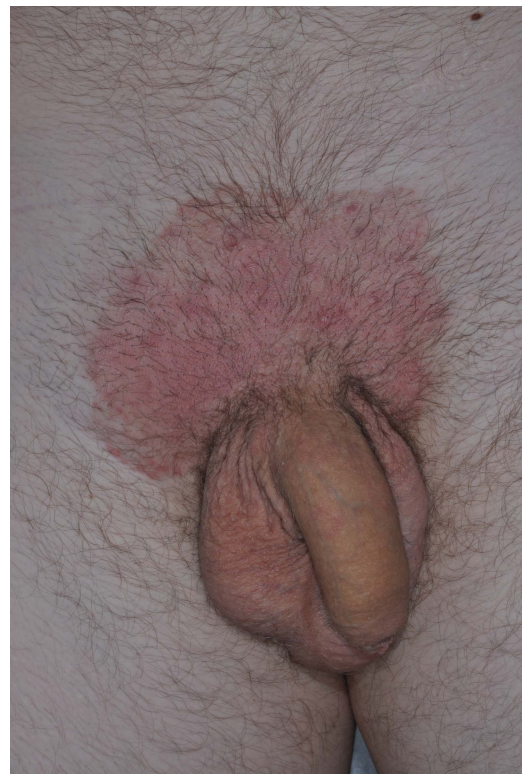


Figure 3 Thirty-year-old man with tinea genitalis.

infections occurred after travelling to South East Asia. Furthermore, additional friction during sexual intercourse can facilitate direct transmission, which is supported by a case series study of Otero *et al*¹⁵ and Bakare *et al*¹⁶ describing prostitutes in Spain and Namibia suffering from tinea cruris. However, there is no information on a potential increase of tinea corporis in prostitutes in South East Asia in the current literature.

Underlying diseases such as diabetes mellitus, immunosuppression or atopic dermatitis are commonly considered to facilitate the acquisition of genital dermatophytoses.^{3 5 7} However, no predisposing diseases were found in our patients. Interestingly, all four patients with severe inflammation in the affected region reported genital shaving on a regular basis. Shaving leads to a mechanical breakage of the epidermal barrier; thereby, epidermal confined dermatophytes gain access to the dermis.¹⁷ Due to disruption of follicles, keratinous material is introduced into the dermis, which operates as a substrate on which the fungal organisms can prosper. Majocchi's granuloma on the legs of women is often associated with frequent shaving of the legs.¹⁸ Therefore, in accordance with the results of Bougrine *et al*,⁷ we suspect that genital shaving promotes continuous spreading of the pathogen into the depths along hair structures and thus deep invasion.

Zoophilic strains of *T. interdigitale*, isolated in six patients, are known to provoke a fulminant inflammatory reaction in humans.¹⁹ In the patients presented here a longer treatment period was necessary (mean 5 weeks). In the recent literature, an example of prolonged therapy was described in a case report of a female veterinary student with a severe inflammatory fungal infection of the pubic area after working in a cattle farm.²⁰ In that case, the pathogen was identified as *T. verrucosum*, also a zoophilic dermatophyte. Likewise, in an infected female patient with Majocchi's granuloma of the vulva caused by *T. mentagrophytes*, her dog was considered the probable source of infection.⁹ She applied topical steroids for many years, assuming that she suffered from an eczema. She was treated for 2 months with oral itraconazole 200 mg twice daily. In contrast, Feldmann *et al*²¹ report on an uncomplicated case with perigenital fungal folliculitis caused by another zoophilic species, *T. erinacei*, which healed completely after 1 week of treatment with itraconazole 2×100 mg a day.

The isolated strains were clearly identified as zoophilic strains of *T. interdigitale*; however, we have no suggestion as to how they were originally transmitted to humans and what the original animal source was. It was not possible to trace the source of infection as the sexual contacts of our patients have been in South East Asia. One of the seven cultures turned out negative. The specimen of this patient revealed hyphae on direct microscopic examination. As the antifungal treatment initiated was successful, we consequently presume a tinea. A potential reason for the negative culture might be a preceding local treatment with a fluocinonid/gramicidin/neomycin/nystatin cream for several weeks.

The seven infections described were most probably sexually transmitted because the tinea appeared first in the pubic and genital areas after sexual contacts. The sexual partner of one female patient clearly had comparable genital lesions earlier. Thus, in our cases heterosexual activity has to be regarded as an important and previously underappreciated means of transmission of *T. interdigitale*. Our current case series represents a unique clinical manifestation only rarely reported in the literature and previously not seen in our clinic. But since it seems unlikely that sexual behaviour significantly affects the prevalence or incidence of dermatophytosis, the proposed criteria of an

STI by Handsfield are not fulfilled.²² Therefore, we believe that tinea genitalis has to be recognised as an infection that may be sexually transmitted, like hepatitis C, methicillin-resistant staphylococcus aureus or amoebiasis, but cannot be considered primarily as an STI.

In conclusion, as the clinical diagnosis of tinea genitalis is often challenging, clinicians should be alert to this entity, especially because the lesions might be misinterpreted as bacterial folliculitis, eczema or psoriasis vulgaris. Particularly when sexual contact is reported, tinea genitalis should be considered. In order to avoid irreversible scarring alopecia, prompt initiation of antifungal treatment is essential and adequate isolation and identification of the pathogen mandatory. Finally, the use of condoms is not protective and an increase of tinea genitalis in the future seems to be possible due to modern travel patterns, especially in young people.

Key messages

- ▶ Sharply demarcated erythematous scaling plaques or pustules in the genital region should raise suspicion of tinea, especially after sexual intercourse in South East Asia.
- ▶ To avoid irreversible scarring alopecia, prompt initiation of antifungal treatment and adequate isolation and identification of the pathogen is essential.
- ▶ Marked inflammatory reaction after starting antifungal treatment is frequent and requires systemic prednisone.

Handling editor Jackie A Cassell

Contributors LI wrote the manuscript, BPP performed DNA sequencing and critically reviewed the manuscript and KRS and RD contributed cases and reviewed the manuscript. LS reviewed the manuscript and conducted the literature review.

Competing interests None declared.

Patient consent Obtained.

Provenance and peer review Not commissioned; externally peer reviewed.

Open Access This is an Open Access article distributed in accordance with the Creative Commons Attribution Non Commercial (CC BY-NC 4.0) license, which permits others to distribute, remix, adapt, build upon this work non-commercially, and license their derivative works on different terms, provided the original work is properly cited and the use is non-commercial. See: <http://creativecommons.org/licenses/by-nc/4.0/>

REFERENCES

- 1 Elewski BE, Hughey LC, Sobera J, *et al*. Fungal diseases. In: Bologna JL, Jorizzo JL, Schaffer JV, *et al*. *Dermatology*. 3rd edn. Philadelphia, Pa: Mosby Elsevier, 2012:1251–84.
- 2 Nenoff P, Krüger C, Schaller J, *et al*. Mycology—an update part 2: dermatomycoses: clinical picture and diagnostics. *J Dtsch Dermatol Ges* 2014;12:749–77.
- 3 Pielop J, Rosen T. Penile dermatophytosis. *J Am Acad Dermatol* 2001;44:864–7.
- 4 Romano C, Ghilardi A, Papini M. Nine male cases of tinea genitalis. *Mycoses* 2005;48:202–4.
- 5 Aridogan IA, Izol V, Ilkit M. Superficial fungal infections of the male genitalia: a review. *Crit Rev Microbiol* 2011;37:237–44.
- 6 Cho HR, Lee MH, Haw CR. Majocchi's granuloma of the scrotum. *Mycoses* 2007;50:520–2.
- 7 Bougrine A, Villeneuve-Tang C, Bouffard D, *et al*. Kerion of the vulva caused by *Trichophyton mentagrophytes*. *J Cutan Med Surg* 2014;18:206–9.
- 8 Margolis DJ, Weinberg JM, Tangoren IA, *et al*. Trichophytic granuloma of the vulva. *Dermatology* 1998;197:69–70.
- 9 Chang SE, Lee DK, Choi JH, *et al*. Majocchi's granuloma of the vulva caused by *Trichophyton mentagrophytes*. *Mycoses* 2005;48:382–4.
- 10 Henry T, Iwen PC, Hinrichs SH. Identification of *Aspergillus* species using internal transcribed spacer regions 1 and 2. *J Clin Microbiol* 2000;38:1510–15.

- 11 Heidemann S, Monod M, Gräser Y. Signature polymorphisms in the internal transcribed spacer region relevant for the differentiation of zoophilic and anthropophilic strains of *Trichophyton interdigitale* and other species of *T. mentagrophytes* sensu lato. *Br J Dermatol* 2010;162:282–95.
- 12 Mølenberg D, Deleuran M, Sommerlund M. Connubial tinea gladiatorum due to *Trichophyton mentagrophytes*. *Mycoses* 2010;53:533–4.
- 13 Mukhopadhyay AK. *Trichophyton rubrum* infection of the prepuce. *Indian J Dermatol Venereol Leprol* 2005;71:130–1.
- 14 Kumar B, Talwar P, Kaur S. Penile tinea. *Mycopathologia* 1981;75:169–77.
- 15 Otero L, Palacio V, Vazquez F. Tinea cruris in female prostitutes. *Mycopathologia* 2002;153:29–31.
- 16 Bakare RA, Oni AA, Umar US, et al. Pattern of sexually transmitted diseases among commercial sex workers (CSWs) in Ibadan, Nigeria. *Afr J Med Med Sci* 2002;31:243–7.
- 17 Gupta S, Kumar B, Radotra BD, et al. Majocchi's Granuloma trichophyticum in an immunocompromised patient. *Int J Dermatol* 2000;39:140–59.
- 18 Lepage JC. Source of Majocchi's granuloma. *J Am Acad Dermatol* 1983;8:260.
- 19 Nenoff P, Herrman J, Gräser Y. *Trichophyton mentagrophytes* sive interdigitale? A dermatophyte in the course of time. *J Dtsch Dermatol Ges* 2007;5:198–202.
- 20 Grunewald S, Paasch U, Nenoff P, et al. Scarring tinea profunda in the pubic area due to *Trichophyton verrucosum*. *Hautarzt* 2006;57:811–13.
- 21 Feldmann R, Riegler E, Breier F, et al. 54-year-old woman with perigenital follicular pustules. Fungal folliculitis caused by *Trichophyton erinacei*. *J Dtsch Dermatol Ges* 2011;9:249–51.
- 22 Handsfield HH. Methicillin-resistant *Staphylococcus aureus* infections in sex partners: what is a sexually transmitted disease? *Clin Infect Dis* 2007;44:1664.